

To Assess the Functional Outcome of Genu Valgus Deformity Treated with Focal Dome Osteotomy by Ilizarov Ring Fixator

Syed Hassan Ali Shah¹, Najeeb ur Rehman¹, Faheem Ahmed Memon², Irshad Ahmed¹, Abbas Memon² and Muhammad Ayub Laghari¹

ABSTRACT

Objectives: To assess the functional outcome of genu valgus deformity treated with focal dome osteotomy by ilizarov ring fixator.

Study Design: Quasi experimental study.

Place and Duration of Study: This study was conducted at the Department of Orthopaedics at Liaquat Medical University Hospital, Hyderabad/Jamshoro Pakistan from 18th Aug 2014 to 17th Aug 2016.

Materials and Methods: Patients that fit in the inclusion criteria were admitted through OPD, all the procedure were explained to the patients. Verbal and written informed consent was taken from the patient. The detailed examination of the effected limb was done and after the surgical procedure and discharge of the patients, assessment was reviewed during patients follow up on every 2 weeks and results was analyzed through SPSS version 21.

Results: The mean age of the patients at the time of the index operation was 23.3 years with SD \pm 8.86 years.(range from 18 to 50 years). Majority of the patients (32 (94.1%) out of 34) mentioned the cosmetic deformity or limp of the knee as the presenting complaint, Out of 34 patients in 23 (67.6) cases the deformity was considered idiopathic in nature, 09 (26.4) of the patients had evidence of nutritional rickets/ osteomalacia, and 02 (5.8) patient had a post-traumatic genu valgum deformity. The mean duration of hospital stay in our setup was 8 days (range, 5 days - 15 days). The mean period of follow-up of patients was 19.8 months (range, 15 months to 29 months). The mean duration of Ilizrove external fixation was 17.65 weeks (range, 15 months to 48 weeks). The mean preoperative HSS score of our patients was 68.2 (range 31-96). Postoperatively the average HSS knee score was 90.1 (67-100). HSS score improved by an average of 22 points (range: 4-51 points) and this improvement was statistically significant ($p = 0.01$) The HSS score was Excellent or good results in 46 (85.18%) of cases and fair or poor results in 8 (14.8%). Only 02 (5.8) cases had deep wound infection that required removal of external fixator at 6 and 8 months respectively. Both cases responded well after external fixator removal.

Conclusion: Focal dome osteotomy with Ilizarov technique has excellent results in most of the patients in our study. It has potential advantages over commonly used open techniques in being minimally invasive, easily reproducible and provides a versatile alternative to currently available methods for fixation of proximal femoral osteotomies.

Key Words: Genu valgum. Correction focal dome osteotomy. Ilizarov technique.

Citation of article: Shah SHA, Rehman N, Memon FA, Ahmed I, Memon A, Laghari MA. To Assess the Functional Outcome of Genu Valgus Deformity Treated with Focal Dome Osteotomy by Ilizarov Ring Fixator. Med Forum 2017;28(4):34-37.

INTRODUCTION

Genu valgum is a latin word used to describe the knock-knee type. Although many children health wise good but have a knock-knee as a series of passes some people maintain or improve this type of hereditary disorders or genetic or bone diseases¹.

¹. Department of Orthopaedics / Orthopaedic Surgery & Traumatology², LUMHS, Jamshoro.

Correspondence: Dr. Syed Hassan Ali Shah, PG Student, Department of Orthopaedics, LUMHS, Jamshoro.
Contact No: 0333-2791242
Email: drhassanortho30@gmail.com

Received: January 10, 2017; Accepted: February 15, 2017

Typical aspect of gait, requiring that each of the swing leg when walking outside to take action without any effort on their legs planted with moving. Not only are the mechanics of gait compromised but also, with significant angular deformity, anterior and medial knee pain are common. These symptoms reflect the pathologic strain on the knee and its patellofemoral extensor mechanism^{2,3}.

Both closed and open wedge osteotomies lead to a secondary translational deformity of the osteotomy fragments, because the osteotomies are being carried out away from the CORA (Centre of Rotation of Angulation). Clinically, a limb with translational deformity of 1.5 cm may not look aesthetic even if it appears straight, because the part distal to the

osteotomy will be shifted medially. Moreover the forces transmitted through the hip, knee and ankle joint following correction will be mal-oriented, which predispose to joint degeneration ⁴.

Focal dome osteotomy also provides excellent apposition of fragments, which leads to a reasonably stable situation after it is fixed with Ilizrov ring fixator, doing correction gradually, (Book: The principles of deformity correction by Dror paley)⁵.

Rational of our study is the angular correction with a dome osteotomy occurs as two matching cylindrical shaped bone ends slide on each other rotating around the central axis of the cylinder. The ACA (axis of correction of angulation) of the dome osteotomy is the central axis of the cylindrical cut. Two- dimensionally, the cylindrical dome osteotomy appears as an arc of circle and its central axis as the centre of the circle. If the ACA (axis of correction of angulation) of the dome osteotomy is centered on the CORA, complete realignment of the proximal and distal bone axes is achieved. The advantages of dome osteotomy are adjustability, large bone to bone contact and stability ⁶. Bone ends maintain maximum bone contact (because of cylindrical shaped osteotomy. Aim of this study is to assess the functional outcome of genu valgus deformity treated with focal dome osteotomy by Ilizrov ring fixator.

MATERIALS AND METHODS

This study was conducted in Department of Orthopaedics at Liaquat Medical University Hospital Hyderabad/Jamshoro Pakistan. Duration of study was two year between 18th Aug 2014 to 17th Aug 2016. Total 34 patients of either gender with age between 18 to 50 years admitted to orthopedic unit with Genu valgus (undergoing focal dome osteotomy with the illizrove fixator for 2 years). Patients were age < 18

years , mentally retarded patients, patients with coxa vara \ coxa valga, and post polio residual deformity were excluded from study

RESULTS

Total 34 focal dome osteotomies done in genu valgus deformity during two year study period. We had 34 patients from which 25 (73.52%) patients were female and 09 (26.47%) patients were male making female to male ratio 1.2:8. The mean age of the patients at the time of the index operation was 23.3 years with SD ± 8.86 years. The mean age of the male patients was 19.4 years and female patients 24.4 years (Table No.1).

Table No.1: Demographic Variable (N=34)

Variable	No.Patients	Percentage
Gender		
• Male	09	26.47%
• Female	25	73.52%
Age		
• 18 to 30 years	17	50%
• 31 to 40 years	13	38.2%
• 41 to 50 years	04	11.7%
Presenting complain		
• Only Limp	16	47.05%
• Limp and pain	10	29.41%
• Limp and gait	6	17.64%
• Fall while walk	2	5.88%
Distribution of causes of genu valgum		
• Idiopathic	23	67.64%
• Rickets/ osteomalacia	9	26.47%
• Post-traumatic	2	5.88%

Table No.2: Preoperative and post operative values of different variables.

Variables	Mean	Range	P -value
pre-operative intermalleolar distance	13.83 cm	9 cm - 21 cm	0.001
Post-operative intermalleolar distance	1.5 cm	0 cm - 6 cm)	
Clinical tibio -femoral angle before operation	23.5o	18o to 30o	0.001
Clinical tibio -femoral angle after operation	6.1o	0o to 10o	
Radiological tibiofemoral angle before operation	22.2o±2.926	16o to 29o	0.001
Radiological tibiofemoral angle after operation	5.1o±2.126	0o to 10o	
Preoperative LDFA	79.23o±2.907	72o to 83o	0.001
Postoperative LDFA	89.13o±2.029	87o to 91o	
Before surgery MAD	19.56±2.029 mm	9 mm to 31 mm	0.001
After surgery MAD	3.7 ±3.875 mm	0 to 5 mm	
Preoperative degree of valgus in frontal plane	25.5°	15° to 45°	0.001
Postoperative degree of valgus in frontal plane	nill	nill	
Preoperative degree of valgus in sagital plane	8.3°	5° to 10°	0.001
Postoperative degree of valgus in sagital plane	nill	nill	
preoperative HSS knee score	68.2	31-96	0.001
Postoperative HSS knee score	90.1	67-100	

Majority of the patients 32 (94.1%) mentioned the cosmetic deformity or limp of the knee as the presenting complaint, 16 (47.05) patient had only limp, 10 (29.4%) patients had pain + limp on presentation, 08 (17.6%) patients complained of gait abnormalities, and only 2 (5.8%) patients had a history of a fall while walking. Out of 34 patients in 23 (67.6) cases the deformity was considered idiopathic in nature, 09 (26.4) of the patients had evidence of nutritional rickets/ osteomalacia, and 02 (5.8) patient had a post-traumatic genu valgum deformity(Table No.1). Preoperative and post operative values of different mean variables shown in table No.2.

Postoperatively the average hospital special Surgery Knee Score HSS knee score was 90.1 (67-100). The HSS score was excellent in 36 (66.6) limbs, good in 10 (18.5), fair in 6 (11.1) limb and poor in 2 (3.7) limb. Excellent or good results were present in 46 (85.18%) of cases and fair or poor results in 8 (14.8%) (Chart No.1). Two cases had a deep wound infection that required removal of external fixator at 6 and 8 months respectively.

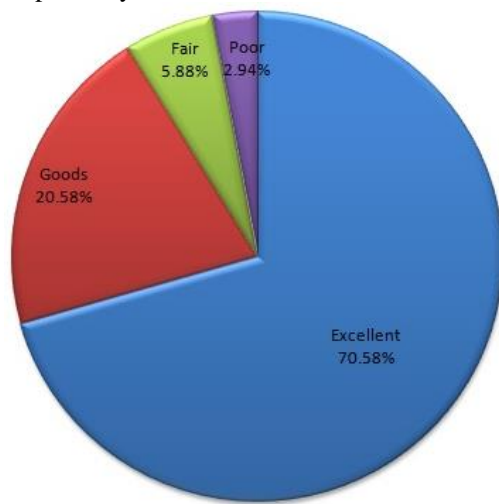


Chart No.1: Hospital Special Surgery Knee Score

DISCUSSION

Genu valgum is the Latin-derived term used to describe knock-knee deformity. While many otherwise healthy children have knock-knee deformity as a passing trait, some individuals retain or develop this deformity as a result of hereditary or genetic disorders or metabolic bone disease¹. The typical gait pattern is circumduction, requiring that the individual swing each leg outward while walking in order to take a step without striking the planted limb with the moving limb. Not only are the mechanics of gait compromised but also, with significant angular deformity, anterior and medial knee pain are common. These symptoms reflect the pathologic strain on the knee and its patellofemoral extensor mechanism^{2,3}.

In our study the mean age of the patients at the time of the index operation was 23.3 years with SD \pm 8.86 years. Age range from 18 to 50 years. 26 (76.4%) were females and 8 (23.5%) were males with female to male ratio of 1:0.30. A study by Kawoosa AA et al⁷ reporting mean age was 21.8 years (range 10-56 years) 17 (65.3%) were females and 9 (34.6%) were male with female to male ratio 1: 0.52. A study by Sad M and Kader A⁸ reporting mean age was 16.4 years (range 12-24 years) 10 (55.6%) were females and 8 (44.4%) were male with female to male ratio 1: 0.8. In current study Majority of the patients 32 (94.1%) mentioned the cosmetic deformity or limp of the knee as the presenting complaint, 16 (47.05) patient had only limp, 10 (29.4%) patients had pain + limp on presentation, 08 (17.6%) patients complained of gait abnormalities, and only 2 (5.8%) patients had a history of a fall while walking. A study by Gupta V et al⁹ reporting in his study the majority of the patients (27 out of 30) mentioned the cosmetic deformity of the knee as the presenting complaint, 11 patients had pain on presentation, 7 patients complained of gait abnormalities, and only 2 patients had a history of a fall while walking.

Our study Out of 34 patients in 23 (67.6) cases the deformity was considered idiopathic in nature, 09 (26.4) of the patients had evidence of nutritional rickets/ osteomalacia, and 02 (5.8) patient had a post-traumatic genu valgum deformity. A study by Kawoosa AA et al⁷ reporting The aetiology of deformity was idiopathic in 12, post-traumatic in 11, post-osteomyelitic in 2 and Blount's disease in one patient.

The mean pre-operative intermalleolar distance was 1.83 cm (range, 9 cm - 21 cm) that improved to a mean post-operative value of 1.5 cm (range, 0 cm - 6 cm) ($p < 0.001$). The mean clinical tibio -femoral angle was 23.5o (range, 18o to 30o) before surgery, that improved to a mean postoperative value of 6.1o (range, 0o to 10o) ($p < 0.001$). A study by Gupta V et al⁹ reporting in his study the mean pre-operative intermalleolar distance was 13.83 cm (range, 9 cm - 21 cm) that improved to a mean post-operative value of 1.5 cm (range, 0 cm - 6 cm) ($p < 0.001$). the mean clinical tibio -femoral angle was 23.5o (range, 18o to 30o) before surgery, that improved to a mean postoperative value of 6.1o (range, 0o to 10o) ($p < 0.001$). In our study The functional outcomes was assessed after removal of fixator and scored according to Hospital Special Surgery Knee Score (HSS). The mean preoperative HSS score of our patients was 70.5 (range 31-96). Postoperatively the average HSS knee score was 93.2 (65-100). HSS score improved by an average of 25 points (range: 5-50 points) and this improvement was statistically significant ($p = 0.01$). A study by Shiha A et al¹⁰, reporting the mean preoperative HSS score of our patients was 68.2 (range 31-96). Postoperatively the average HSS knee score was 90.1 (67-100). In this

study the HSS score was excellent in 36 (66.6) limbs, good in 10 (18.5), fair in 6 (11.1) limb and poor in 2 (3.7) limb. Excellent or good results were present in 46 (85.18%) of cases and fair or poor results in 8 (14.8%). In present study Two cases had a deep wound infection that required removal of external fixator at 6 and 8 months respectively. Both cases responded well after external fixator removal. None of the cases had other complications like knee stiffness, recurrence of deformity, shortening, reversal of deformity, or non-union of the osteotomy site. A study by Gupta V et al⁹ reporting in his study two cases had a deep wound infection that required implant removal at 6 and 8 months respectively. Both cases responded well after implant removal. None of the cases had other complications like knee stiffness, recurrence of deformity, shortening, reversal of deformity, or non-union of the osteotomy site.

CONCLUSION

Focal dome osteotomy with Ilizarov technique has excellent results in most of the patients in our study. It has potential advantages over commonly used open techniques in being minimally invasive, easily reproducible and provides a versatile alternative to currently available methods for fixation of proximal femoral osteotomies.

Conflict of Interest: The study has no conflict of interest to declare by any author.

REFERENCES

1. Wieman JM, Tryon C, Szalay EA. Physeal stapling versus 8-plate hemiepiphyodesis for guided

- correction of angular deformity about the knee. *J Pediatr Orthop* 2009;481-5.
2. Pistevos G, Duckworth T. The correction of genu valgum by epiphyseal stapling. *J Bone Joint Surg* 1977;59-B:72-6.
3. Burghardt RD, Herzenberg JE, Standard SC, Paley D. Temporary hemiepiphyseal arrest using a screw and plate device to treat knee and ankle deformities in children: a preliminary report. *J Child Orthop* 2008;2(3):87-97.
4. Paley D. *Book the principles of deformity correction* 2010:110-113.
5. Gautam VK, Kumar R, Mishra P. Focal dome osteotomy for correction of genu valgum. *Ind J Orthop* 2002;36(6):63-69.
6. Kawoosa AA, Wani IH, Dar FA, Sultan A, Qazi M, Halwai MA. Deformity Correction about Knee with Ilizarov Technique: *Orrttopediia Traumatologia Rehabilitacja* 2015;17:6(6);587-592.
7. Sad M, Kader A. The correction of Genu Valgum by a reversed dome osteotomy in the supracondylar area of the Femur: *Pan Arab J Ortho Trauma* 2002; 6(2):199-202.
8. Gupta V, Kamra G, Singh D, Pandey K, Arora S. Wedgeless 'V' shaped distal femoral osteotomy with internal fixation For genu valgum in adolescents and young adults. *Acta Orthop Belg* 2014;80:234-240.
9. Shiha A, Alam el-deen M, Khalifa R, Kenawey M. Ilizarov gradual correction of genu varum deformity in adults. *Acta Orthop Belg* 2009;75: 784-791.