

# A Histopathological Study of Cholecystectomy Specimens in Gujrat – Pakistan

Abdul Rauf<sup>1</sup>, Qamar Zaman Choudhary<sup>2</sup> and Muhammad Ali<sup>3</sup>

## ABSTRACT

**Objective:** To study the pattern of histopathological lesions in surgically resected gallbladders.

**Study Design:** A retrospective / descriptive study.

**Place and Duration of Study:** The study was conducted at the Department of Pathology, Nawaz Sharif Medical College, University of Gujrat, Pakistan from Jan 1, 2015 to June 30, 2017 (2.5 years).

**Materials and Methods:** The study consists of 136 gallbladder specimens that were studied histologically by the author. These specimens were received at department of Pathology and in a private hospital in Gujrat. The data of all the cases was retrieved from registers of histopathology. It was compiled and analyzed from various angles including gender, age, cholelithiasis and histopathological lesions. The findings were compared with other studies.

**Results:** There were 77 females and 31 males in the study with a M:F ratio of 1:3.4. Cholelithiasis was seen in 88.2% (120) of cases. Chronic cholecystitis was present in 77.9% (106) of cases while acute cholecystitis was seen in 19.1% (26). Cholelithiasis was seen in 3.7% (5) and cholesterol polypi in 1.5% (2) of cases. Carcinoma was seen in 5 patients comprising 3.7% of all cases.

**Conclusion:** The findings in our study are similar to the most studies in literature. Gallstones and chronic cholecystitis were seen in the majority of cases.

**Key Words:** Gallbladder, Gallstones, Cholelithiasis, Cholecystitis

**Citation of articles:** Rauf A, Choudhary QZ, Ali M. A Histopathological Study of Cholecystectomy Specimens in Gujrat – Pakistan. Med Forum 2018;29(4):6-10.

## INTRODUCTION

Surgical removal of gallbladder is a standard treatment for gallstones and other diseases.<sup>1</sup> Most of the patients are females and undergo cholecystectomy in fourth and fifth decades of life.<sup>2</sup> Gallstones are seen in a majority of specimens submitted for histopathology along with a variety of histopathological lesions.<sup>3</sup> Benign lesions are much more common than malignant. There were only about 1% (n=7) malignant cases in a study of 740 cases.<sup>4</sup> Chronic cholecystitis is the most frequently encountered histopathological lesion.<sup>5</sup> Other benign lesions include acute cholecystitis, xanthogranulomatous cholecystitis, eosinophilic cholecystitis, cholelithiasis, polypi, adenomyosis, intestinal metaplasia, pyloric metaplasia and hyperplasias etc.<sup>6</sup> Majority of the malignant neoplasms are carcinomas and adenoacarcinoma in commonest amongst these.<sup>5</sup> Most malignancies of gallbladder are diagnosed late in their course leading to poor prognosis.<sup>7</sup>

There is variation in incidence of gallbladder cancer in various parts of world. The areas with high incidence include some South American countries and Northern India. Higher incidence is reported from southern part of Pakistan in Karachi.<sup>8</sup>

Generally, all the gallbladder specimens are submitted for histopathology in most centers but some workers have termed it a waste of sources and a burden on histopathologists.<sup>9,10</sup> On the other hand, some studies have opposed the idea of selective histopathology of gallbladders.<sup>11,12</sup> There is no previous study of gallbladder histopathology in Gujrat and adjoining areas. The purpose of this effort is to study the basic pattern of gallbladder disease in this area of country in comparison with other studies within and outside country.

## MATERIALS AND METHODS

This is a retrospective study of all the patients whose gallbladders were received by the author for histopathology from Jan 2015 to June 2017 (2.5 years). These were examined grossly and representative sections were taken for processing. Slides were prepared and stained with hematoxylin and eosin. The gross examination of all the specimens and reporting of histopathology slides were done by the author himself as there is no other histopathologist available in the district for consultation or discussion. The grossing and reporting were performed at two places i.e. Pathology department, Nawaz Sharif Medical College in University of Gujrat and at a private hospital in Gujrat

<sup>1</sup>. Department of Pathology / General Surgery<sup>2</sup>, Nawaz Sharif Medical College, University of Gujrat.

<sup>3</sup>. Department of General Surgery, Aziz Bhatti Shaheed Teaching Hospital Gujrat.

Correspondence: Dr. Abdul Rauf, Assistant Professor, Department of Pathology, Nawaz Sharif Medical College, University of Gujrat, Gujrat.

Contact No: 0300-6209693

Email: abdulrauf64@live.com

Received: December, 2017; Accepted: February, 2018

city. The records of all the patients were retrieved and compiled with the help of Microsoft Excel software. These were analyzed from various angles including gender, age, cholelithiasis and various histopathological lesions. The findings were compared with national as well as international studies.

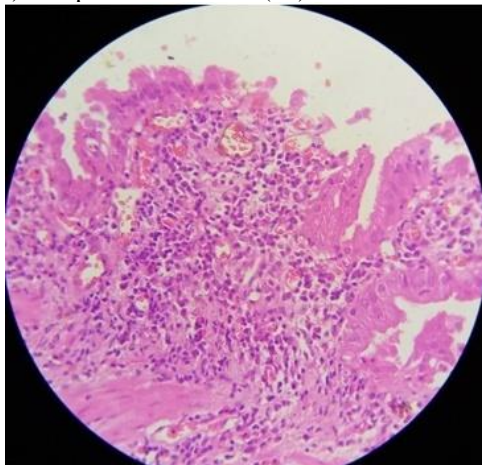
**RESULTS**

The study consisted of 136 patients. There were 77% (105) females as compared to 23% (31) males with MF ratio of 1:3.4. Age of 133 patients was known. Mean age was 44 years and age ranged from 14-80 years. Most of the patients were in fourth decade i.e. 29% followed closely by 27% in fifth decade. So the age range of 31-50 years i.e. fourth and fifth decades contained 56.4% of patients. Gender wise age distribution is shown in Table 1. Youngest patient was a 14 year old female. Two male patients were the oldest with age of 80 years each.

**Table No. 1: Age and gender distribution of cases (n=133).**

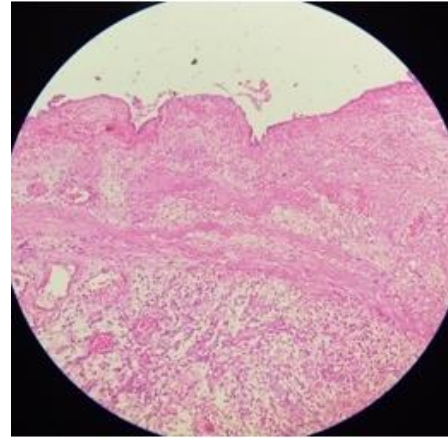
Age group	Males	Females	Total	%
11-20 years	1	1	2	1.5
21-30 years	4	19	23	17.3
31-40 years	6	33	39	29.3
41-50 years	11	25	36	27.1
51-60 years	4	15	19	14.3
61-70 years	2	10	12	9.0
71-80 years	2	0	2	1.5
<b>Total</b>	<b>30</b>	<b>103</b>	<b>133</b>	<b>100.0</b>

Operative procedure was known in 94 patients. It was laparoscopic cholecystectomy in 91% (86) and open cholecystectomy in 9% of patients. Neoplastic lesions were found in 5 (3.7%) gallbladders and were malignant in all these cases. The remaining 131(96.3%) gallbladders were having no neoplastic pathology. Cholelithiasis was the predominant pathology found in 88.2% (120) of cases. Chronic cholecystitis (Fig-1) was seen in 77.9% (106) of cases and acute cholecystitis (Fig-2) was present in 19.1% (26) of cases.



**Figure No.1: Chronic Cholecystitis (H&E, X400) showing intense infiltrate of lymphocytes and plasma cells.**

Some of the gallbladders contained more than one histopathological finding like one case of acute cholecystitis coexisted with adenocarcinoma. Fourteen cases of acute cholecystitis contained necrotizing/gangrenous features accounting for 10.3% of all cases.

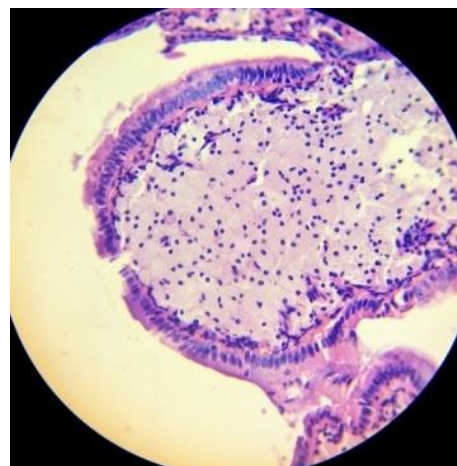


**Figure No. 2: Acute Cholecystitis (H&E, X200) showing marked edema of wall and surface ulceration of the lining epithelium.**

The frequencies of other lesions are mentioned in Table 2.

**Table No.2: Gross and microscopic findings in gallbladders (n=136).**

Finding	#	%
Gallstones	120	88.2
Chronic cholecystitis	106	77.9
Acute cholecystitis	26	19.1
Adenocarcinoma	5	3.7
Cholestrolosis	5	3.7
Cholesterol polyps	2	1.5
Empyema	1	0.7
Xanthogranulomatous cholecystitis	1	0.7
Spongiotic hyperplasia	1	0.7

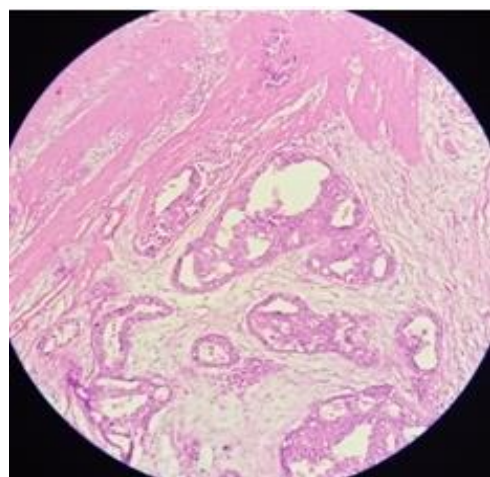


**Figure No. 3: Cholestrolosis (H&E, X400), Mucosa containing many foamy macrophages.**

All the five cases of malignancy were carcinomas comprising four cases of adenocarcinoma (Fig-4) and one case of an undifferentiated carcinoma.

**Table No. 3: Comparison of present study with some recent studies.**

	Present Study	Shah H 15	Khan S 16	Memon13	Awasthi14	Thaker & Singh 17
Year (Published)	2017	2016	2013	2011	2015	2017
Total cases	136	400	360	282	732	800
M:F ratio	1:3.4	1:2.4	1:4.7	1:2.9	1:2.6	1:4
Mean Age (years)	44	43	37	45	43.2	42
Age range	14-80	17-75	14-70	15-75	12-81	8-80
4 <sup>th</sup> decade	29.3%	31.2%	30.2%	31.9%	27.2%	27.5%
5 <sup>th</sup> decade	27.1%	32.5%	22.8%	31.9%		
Chronic Cholecystitis	77.9%	82.2%	77.7%	64.8%	97.1%	80.4%
Acute Cholecystitis	19.1%	12.2%	2.7%	31.5%	0.8%	0.25%



**Figure No. 4: Adenocarcinoma (H&E, X200). Neoplastic glands infiltrating the tissue deeper to muscle layer.**

All the five patients were females and mean age was 56 years.

**Table No.4: Frequency of adenocarcinoma in various studies.**

Study	All Malignant cases	Adeno-carcinoma cases	%
Present Study	5	4	80
Shah H et al.15	8	8	100
Khan S et al.16	9	8	88.9
Memon W et al.13	4	4	100
Dowerah & Deori.20	8	6	75
Kumari NS et al.22	1	1	100
Sharma & Choudhury 23	3	3	100
khan F et al.19	2	2	100
Thaker & Singh.17	1	1	100
<b>Total</b>	<b>41</b>	<b>37</b>	<b>90.2</b>

## DISCUSSION

Gallbladder is a common surgically removed structure from human body due to pathological lesions. Its lesions are more common in females.<sup>13,14</sup> The M:F ratio in our study is 1:3.4 and this is comparable with several studies as is given in Table 3. Mean age of 44 years and age range of 14-80 years are also comparable with other studies in Table 3.

Most of the patients were found in fourth decade in our study i.e. 29.3%. Other authors have reported most cases in fourth decade like Khan S, Awasthi and Thaker & Singh.<sup>14,16,17</sup> Fourth decade was followed closely by fifth decade with 27.1% of cases in our study. The difference between cases in fourth and fifth decade is not much in our study, a finding similar to Shah H and Memon.<sup>13,15</sup> In the study of Shah H, there are slightly more cases in fifth decade i.e. 32.5% as compared to 31.2% in fourth decade.<sup>15</sup> There is equal frequency of cases in fourth and fifth decades in the study of Memon.<sup>13</sup> Collectively, the majority of gallbladder cases are seen in fourth and fifth decade that comprised 56.4% of cases in the present study. This finding is similar to the studies of Chauhan with 51%, Khan S with 53% and Memon with 63.8% of cases.<sup>3,13,16</sup>

The frequency of neoplastic lesions in our study (3.7%) is similar to a frequency of 5% in the study of Chauhan.<sup>3</sup> Gallstones were seen in a high frequency of 88.2% of our cases. The finding is similar to 89.9% and 91.8% reported by Mazlum and Dattal respectively.<sup>6,18</sup> Other authors have reported even higher frequency of gallstones in their studies like Awasthi: 95.2% and Khan F et al: 98.5%.<sup>14,19</sup> Chronic cholecystitis is the histopathological lesion most frequently encountered in resected gallbladders. Our finding of 77.9% cases of this lesion is in comparison with most others studies as in Table 3.

There were 19.1% cases of acute cholecystitis in our study. Our result is closer to that of Shah H at 12.2%.<sup>15</sup> There is wider variation in frequencies of this lesion as compared to chronic cholecystitis in various studies like

0.25% in the study of Thaker & Singh and 0.8% in the study of Awasthi on lower side and a frequency of 31.5% on higher side by Memon et al.<sup>13,14,17</sup>

Various non neoplastic lesions found in smaller frequencies in gallbladders in present study were cholesterosis (3.7%), cholesterol polyps (1.5%), empyema (0.7%), xanthogranulomatous cholecystitis (0.7%) and spongiotic hyperplasia (0.7%). The cases of these lesions are mentioned in small frequencies in other studies.<sup>5,6,20</sup>

Gallbladder malignancy is seen in a few cases. There were 3.7% malignant cases in our study, a finding closer to that of Khan S et al at 2.5% and Shah et al at 2%.<sup>15,16</sup> On the other hand Khan UA from Lahore has reported malignancy in 7.2% of cases in his study.<sup>11</sup> Similarly Dowerah & Deori have reported a higher rate of 7.7%.<sup>20</sup>

Gallbladder malignancy is more common in females and is most commonly an adenocarcinoma. Among the five cases of malignancy there were four cases of adenocarcinoma and one case of an undifferentiated carcinoma. All cases were females and mean age was 56 years. The mean age of 56 years is in correspondence with that of 53.4 years reported by Kumar. The higher frequency in females is evident in other studies.<sup>15,16</sup> The high frequency of adenocarcinoma in present study is in accordance with other studies in Table 4.

There was only one case of an undifferentiated carcinoma in present study. Other less common varieties of gallbladder malignancies not found in present study presumably due its small size include adenosquamous carcinoma, squamous cell carcinoma, small cell/ neuroendocrine carcinoma and non-Hodgkin lymphoma.<sup>22-23</sup>

## CONCLUSION

The main findings in present study from a small district are in accordance with other studies. Gallstones and chronic cholecystitis are very common. Acute cholecystitis is also seen in a significant number of cases. The frequency of malignant cases appears moderate in this part of country.

### Author's Contribution:

Concept & Design of Study:	Abdul Rauf
Drafting:	Qamar Zaman Choudhary, Muhammad Ali
Data Analysis:	Qamar Zaman Choudhary,
Revisiting Critically:	Abdul Rauf, Qamar Zaman Choudhary
Final Approval of version:	Abdul Rauf

**Conflict of Interest:** The study has no conflict of interest to declare by any author.

## REFERENCES

1. Abraham S, Rivero HG, Erlich IV, Griffith LF, Kondamudi VK. Surgical and Nonsurgical Management of Gallstones. *Am Fam Physician* 2014;89(10):795-802.
2. Verma R, Binnani N, Kumar V, Gupta N. Study of Various Histopathological Lesions In Resected Gall Bladder Specimens: A Study In Consecutive 898 Cholecystectomies. *Int J Sci Res Manage (IJSRM)* 2017;5(3):5216-5221
3. Chauhan HM, Damor NT, and Jadav HR. Histological study of human gallbladder. *Int J Biomed Adv Res (IJBAR)* 2013;4(9):597-601
4. Zahrani IH, Mansoor I. Gallbladder pathologies and cholelithiasis. *Saudi Med J* 2001;22(10):885-889.
5. Khatri AM, Haider G, Hasnain A, Ahmed MU, Mumtaz N, Wasty WH, et al. Is Routine Histopathology of Gall Bladder After Laparoscopic Cholecystectomy Needed? A Local Perspective. *Pak J Med Dent* 2016;5(2):33-37.
6. Mazlum M, Dilek FH, Yener AN, Tokyol C, Aktepe F, Dilek ON. Profile of Gallbladder Diseases Diagnosed at AfyonKocatepe University: A Retrospective Study. *Turkish J Pathol* 2011;27(1):23-30.
7. Lobo L, Prasad K, Satoskar RR. Carcinoma of the Gall Bladder: A Prospective Study in a Tertiary Hospital of Bombay, India. *J Clin Diagnostic Res* 2012 May (Suppl-2), Vol-6(4):692-695.
8. Randi G, Franceschi S, La Vecchia C. Gallbladder cancer worldwide: Geographical distribution and risk factors. *Int J Cancer* 2006;118:1591-1602.
9. González RJR, Flores AG, Maldonado LMP, Elizondo JAD, Eguía JJM, Quintana AB. Gallbladder selection for histopathological analysis based on a simple method: a prospective comparative study. *Ann R Coll Surg Engl* 2012; 94(3): 159-164.
10. Byars JPD, Pursnani K. An Alternative Approach to Sending All Gallbladders for Histology Following Cholecystectomy? *Surg Sci* 2012;3:15-20.
11. Khan UA, Iqbal M, Aslam I, Gondal KM, Alam S. Importance of Routine Histopathology of Gallbladder after Elective Cholecystectomy for Gallstones. *Annals of KEMU* 2016;22(2):96-101
12. Siddiqui FG, Memon AA, Abro AH, Sasoli NA, Ahmad L. Routine histopathology of gallbladder after elective cholecystectomy for gallstones: waste of resources or a justified act? *BMC Surg* 2013;13:26.

13. Memon W, Khanzada TW, Samad A, Kumar B. Histopathological Spectrum of gall bladder specimens after cholecystectomy. *Pak J Med Sci* 2011;27(3):553-556.
14. Awasthi N. A retrospective histopathological study of cholecystectomies. *Int J Health Allied Sci* 2015;4:203-6.
15. Shah H, Khan MA, Shah W. Histopathological pattern of 400 cholecystectomy specimens. *J Postgrad Med Inst* 2016; 30(3): 250-3.
16. Khan S, Jetley S, Husain M. Spectrum of histopathological lesions in cholecystectomy specimens: A study of 360 cases at a teaching hospital in South Delhi. *Arch Int Surg* 2013;3:102-5.
17. Thaker BD, Singh K. Histopathological spectrum of cholecystectomy specimen in Government Medical College Jammu - a hospital based study. *Int J Sci Res* 2017; 6(6):59-60.
18. Dattal DS, Kaushik R, Gulati A, Sharma VK. Morphological spectrum of gall bladder lesions and their correlation with cholelithiasis. *Int J Res Med Sci* 2017;5:840-6.
19. Khan F, Manzoor A, Haq MBU. Histological Examination of Cholecystectomy Specimens. *J Rawalpindi Med Coll* 2014;18(2):240-242.
20. Dowerah S, Deori R. A study of benign histopathological changes in cholecystectomy specimen: experience at a referral hospital. *Int J Contemporary Med Res* 2016;3(8): 2392-2394.
21. Kumari NS, Sireesha A, Srujana S, Kumar OS. Cholecystectomies – A 1.5 year histopathological study. *Int Archives Integrated Med* 2016; 3(9):134-139.
22. Sharma I, Choudhury D. Histopathological patterns of gall bladder diseases with special reference to incidental cases: a hospital based study. *Int J Res Med Sci* 2015;3(12):3553-3557.