

Effectiveness of Vacuum-Assisted Closure Therapy as a Pretreatment for Split Thickness Skin Grafts

VAC Dressing as a pretreatment of Spilt Thickness Skin Grafting

Moiz Sadiq¹, Fahad Hanif Khan², Syed Sheeraz ur Rahman³ and Obaid-ur-Rahman²

ABSTRACT

Objective: To assess the effectiveness of vacuum assisted closure (VAC) dressing as a pretreatment of split thickness skin grafting versus routine normal saline dressings.

Study Design: Randomized control study

Place and Duration of Study: This study was conducted at the Department of Plastic and Reconstructive Surgery, Liaquat National Hospital, Karachi from June-December, 2017.

Materials and Methods: All patient fulfilling the inclusion and exclusion criteria were asked for a consent and enrolled in the study. Patient of either sex, age, from 20 – 50 years with traumatic and post-surgical acute wounds (within a week) on upper or lower limbs only, requiring split thickness skin grafting were included in the study. Statistical package for social sciences (SPSS) version 18 was used for data analysis. Chi-square test was used for significant co-relations with 95% confidence interval.

Results: A total of 92 patients with traumatic and post-surgical acute wound requiring split thickness skin grafting were included in this study. Forty six in group A were treated by vacuum assisted closure (VAS) and 46 were treated with normal saline. Effectiveness was significantly higher in group A than group B (80.4% vs. 56.5%; p=0.014).

Conclusion: Split-thickness skin grafting provides a simple one-stage reconstructive option for skin and soft tissue defects. The use of VAC therapy is an effective and a safe adjunct to conventional treatment modalities for the management of wound.

Key Words: Vacuum assisted closure, skin grafting, direct closure, wound coverage

Citation of articles: Sadiq M, Khan FH, Rahman SS, Rahman O. Effectiveness of Vacuum-Assisted Closure Therapy as a Pretreatment for Split Thickness Skin Grafts. Med Forum 2018;29(9):14-17.

INTRODUCTION

Wound has been a challenge for healers since ancient times. Usually open wound is managed with repeated dressings and multiple debridements. In complex wounds with soft tissue loss, healing can occur by secondary intention or augmented with grafts or flaps¹. Among this skin grafting has been one of the oldest armamentarium of surgeon for the wounds which cannot be close primarily^{2,3,4}. Wounds with tissue loss if allowed to heal by secondary Intention without skin grafting demonstrate greater degree of contracture and are more prone to hypertrophic scarring³. Skin graft requires a vascular bed and will seldom take in expose bone, cartilage or tendon devoid of their periosteal, perichondrium or paratenon. The major causes of skin graft loss are the result of the formation

of seroma or hematoma under the graft that interferes directly with the imbibitions and revascularization process, and the infection of the graft that frequently leads to partial or total graft loss^{3,5}. So graft take can be facilitated by different techniques like tie-over bolster dressings, quilting stitch and vacuum assisted closure therapy. Among these, vacuum-assisted closure (VAC) therapy is a new modality of managing open wound. It is an effective and inexpensive treatment for acute and chronic wounds and is being used increasingly in all surgical specialties⁶. The use of vacuum assisted closure therapy in dressing of split skin grafts has been shown to promote healing by a number of mechanisms, including reducing interstitial edema, promoting angiogenesis and by opposing bacterial colonization^{7,9}. Normally, the vacuum assisted closure therapy is recommended for treatment of traumatic wounds, diabetic wounds, pressure and venous ulcers but its use, to minimize interstitial fluid and hematoma before grafting to prevent the graft loss is very limitedly addressed¹⁰. The only study that come across by Sadiq M, et al. showed a significant improvement in graft take (>95%) in patients who were dressed with VAC therapy as compared to 18% of the patients who were dressed with routine dressing (with normal saline) prior to grafting¹. There is lack of literature on this topic as the sample had unequal number of patients in both groups.

¹. Department of Plastic and Reconstructive Surgery / Plastic Surgery² / General Surgery³, Liaquat National Hospital, Karachi.

Correspondence: Fahad Hanif Khan, Resident, Plastic Surgery department, Liaquat National Hospital, Karachi.
Contact No: 0333-3032360
Email: dr.fhkhan@hotmail.com

MATERIALS AND METHODS

This is a randomized control trial conducted at the department of Plastic and Reconstructive surgery, Liaquat National Hospital, Karachi over a period of 6 months from June – December, 2017. Patient of either sex, age, from 20 – 50 years with traumatic and post-surgical acute wounds (within a week) on upper or lower limbs only, requiring split thickness skin grafting were included in the study. The following patients were excluded from selection

1. Deep wounds with exposed bone, neuro-vascular structure or tendon
2. Wounds with positive bacterial culture and sensitivity prior to grafting.
3. Patient with co-morbidities.
4. Patient with impair wound healing (e.g. chemotherapy, corticosteroids, or local irradiation therapy).
5. Wounds involving joints (due to difficulty in VAC dressing application).

Informed and written consent was taken. The patients were randomly allocated in two groups (Group A and B) using lottery method. In Group A, 46 patients were applied Vacuum Assisted Closure (VAC) dressing 10 days prior to split thickness grafting. The VAC sponge was cut to match the contour of the wound and then secured to the surrounding skin using an adherent, occlusive dressing. The VAC dressing was placed at continuous -125 mm Hg pressure. VAC dressing was changed on every third day for ten days. In Group B, 46 patients were dressed daily with the routine 0.9% normal saline soaked gauze. The dressings in both groups were removed after 10 days. The length and width of the wound was measured with a ruler for the area of wound prior to grafting. Split thickness skin grafting was done using Watson knife, which was meshed using a Derma carrier of 1x1.5. The STSG was secured to the recipient site using circumferential staples, followed by placement of a non-adherent paraffin gauze dressing. During the postoperative period, attempts were made to keep the affected area immobilized by bed rest or a splint. The graft was checked at 5th post-operative day and the wound was evaluated by using a ruler for grafted area [Length (cm) × breadth (cm) = area (cm²)]. The percentage of grafted area was taken by dividing the grafted area by the total wound area multiplying by 100 [Grafted area percentage: grafted area cm² / wound area cm² × 100]. Assessment of graft take was done by a single consultant surgeon and only ≥ 95% of graft take was considered as “effective”. All data will be collected in pre designed proforma by principle investigator. To minimize bias all patients were managed by a senior investigator for grafting, who was unaware of the study group of the patients.

Statistical package for social sciences (SPSS) version 18 was used for data analysis. Chi-square test was used for significant co-relations with 95% confidence interval.

RESULTS

Ninety two patients with traumatic and post-surgical acute wounds requiring split thickness skin grafting were included in this study. Patients were randomly allocated into two groups. Forty six patients in group A were treated by vacuum assisted closure (VAS) and 46 were treated with normal saline. In both groups, 31 to 40 years of age patients were commonly. The average age of the patients was 37.14 ± 6.76 years (table I). Out of 92 patients, 40(43.5%) were male and 52(56.5%) were female, with 25 (54.3%) males in group A as compared to 15 (34.6%) in group B, while 21 (45.6%) females in group A versus 31 (67.3%) in group B. Regarding etiology of wound, trauma was observed in 33 (35.9%) cases and post surgical defect was observed in 59 (64.1%) patients (figure I). Fifty four (31 in group A vs 23 in group B) patients had wounds on upper limb as compared to 38 (15 vs 23 in group A and B, respectively) on lower limbs.

Table No.I: Characteristics of patients with respect to groups (n=92)

Variables	Group A (VAC Dressing) (n=46)	Group B (Normal Saline) (n=46)	Mean ± SD
Age (years)	35.85 ± 6.73	38.43 ± 6.62	37.14 ± 6.76
Size of Wound (cm)	19.33 ± 5.59	19.37 ± 4.45	19.35 ± 5.03
Duration of wound (days)	4.76 ± 1.33	4.57 ± 1.39	4.66 ± 1.43

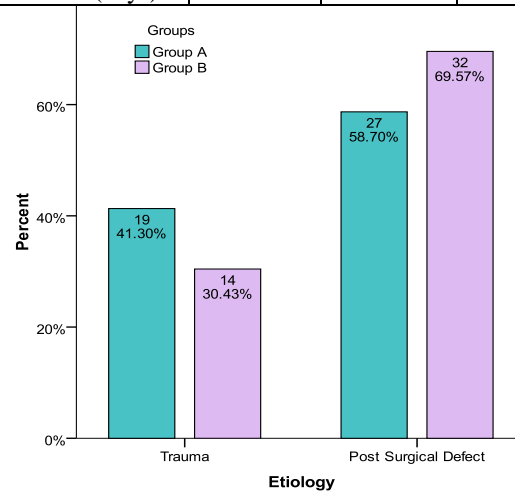


Figure No.I: Etiology of the patients with respect to groups (n= 92)

Table No.2: Effectiveness of group A versus group B (n= 92).

Graft take $\geq 95\%$	Group A (VAC Dressing) (n= 46)	Group B (Normal Saline) (n=46)	Total (n= 92)	P-Value*
Yes	37 (80.4%)	26 (56.5%)	63 (68.5%)	0.014
No	9 (19.6%)	20(43.5%)	29 (31.5%)	

*Chi-Square test

Effectiveness was defined as graft take $\geq 95\%$ of the surface area, which was significantly higher in group A than group B (80.4% vs. 56.5%; p-value: 0.014) as shown in table II. Effectiveness was significant for vacuum dressings in those cases whose duration of wound was 1-4 days (p=0.036), wounds after previous surgery (p-value: 0.039) and was irrespective to the size of wound (P-value: 0.02). No significant difference was observed between groups for lower and upper limbs (p-value: 0.80).

DISCUSSION

Vacuum-assisted closure (VAC) therapy is a new modality of managing open wounds which is taking its place as an effective and inexpensive treatment for acute and chronic wounds and is being used increasingly in all surgical specialties¹¹.

In this present study the mean age of the patients was 37.14 ± 6.76 years. Out of 92 patients, 40 (43.5%) were male and 52 (56.5%) were female. In a study by Saaiq et al¹ in 100 patients, 86 (86%) were males. The age ranged from 13-65 years, with a mean of 33.07 ± 13.60 years.

A number of adjuvant therapies such as use of skin substitutes, growth factors and hyperbaric oxygen have been employed to expedite wound healing. VAC therapy was found as a better alternative in this regard as it is more economical and safer¹². The present findings are in conformity with those of other published studies¹²⁻¹⁴. We observed graft take of $>95\%$ if vacuum assisted closure (VAC) dressing was used as a pretreatment for wounds requiring split thickness skin grafting versus routine normal saline dressing. The effectiveness was significantly high in group A than group B (80.4% vs. 56.5%; p-value: 0.014). Several published studies have successfully used VAC dressings for securing skin grafts postoperatively, especially in wounds with exudative, irregular, or mobile recipient beds and in difficult anatomic locations. It has been reported to stabilize the skin graft and conform it well to the shape of recipient bed, remove edema fluid, decrease bacterial counts, and provide a secured dressing. All these factors further improve the graft survival and reduce the need for repeat skin grafting¹⁵⁻¹⁷.

Effectiveness was significant between groups in those cases whose duration of wound was 1 to 4 days (p=0.036) and in post-surgical wounds (p=0.039). Other published studies have also shown fast healing with VAC therapy¹⁸⁻²⁰. A variety of factors have been described to account for the accelerated healing. VAC therapy decontaminates the wound and removes surface off exudates, which contain large amounts of proteases. Fluid removal helps with localized edema that otherwise cause an increase in interstitial pressure with consequent occlusion of microvasculature and lymphatics, decreased nutrient, and oxygen delivery⁽¹⁸⁾. Protein degradation enzyme is released with metabolic waste accumulation and increased bacterial colonization, which causes capillary damage and hypoxia. Vacuum therapy also provides a moist environment for granulation tissue formation, which allows for faster re-epithelialization of the wound surface. Angiogenesis is stimulated, which improves tissue oxygenation and tissue reconstruction^{21,22}. Micromechanical forces exerted on wound surface by low pressure suction are also important. This mechanism mimics the stretch-induced cell proliferation typically operative in tissue expansion phenomenon seen elsewhere in the body^{23,24}. Split-thickness skin grafting is simple to perform and has a low morbidity. Owing to its low cost, VAC therapy can provide an economical alternative to the other available costly local wound management measures. Such economic implications of wound management are particularly important in the context of our poor patients. Cost effectiveness has also been reported in terms of shortened hospital stays, and decreased overall medical cost in the published literature^{25,26}.

CONCLUSION

Split-thickness skin grafting (STSG) provides a simple one-stage reconstructive option for skin and soft tissue defects. The use of VAC therapy is an effective and safe adjunct to conventional and established treatment modalities for the management of wound infection. VAC therapy should be employed in the pre-treatment of wounds planned to be reconstructed with STSG, given its significant advantages in the wound bed preparation compared with traditional normal saline gauze dressings.

Author's Contribution:

Concept & Design of Study: Moiz Sadiq
 Drafting: Moiz Sadiq, Syed Sheeraz ur Rahman
 Data Analysis: Fahad Hanif Khan, Obaid-ur-Rahman
 Revisiting Critically: Moiz Sadiq, Syed Sheeraz ur Rahman
 Final Approval of version: Moiz Sadiq

Conflict of Interest: The study has no conflict of interest to declare by any author.

REFERENCES

- Saaq M, Uddin H, Khan MI, Chaudhery SM. Vacuum-assisted closure therapy as a pretreatment for split thickness skin grafts. *J Coll Physician Surg Pak* 2010;20(10):675-79.
- Memon AS, Shaikh NA, Samo KA, Awan A. Split thickness skin grafting for wounds in a general surgical setting: our experience. *Med Channel* 2007;13(1):15-17.
- Thorne CH, Mustore TA. Grabb and Smith's plastic surgery. Techniques and principle in plastic Surg 2007;6:3-14.
- Akhavani MA, Mckinnell T, Kang NV. Quilting of full thickness grafts in the hand. *J Plast Reconstr Aesthet Surg* 2010;63:1534-37.
- Llanos S, Danilla S, Barraza C, Armijo E, Piñeros JL, Quintas M, et al. Effectiveness of Negative Pressure Closure in the Integration of Split Thickness Skin Grafts. A Randomized, Double-Masked, Controlled Trial. *Ann Surg* 2006;244(5): 700-05.
- Shrestha BM, Nathan VC, Delbridge MS, Parker K, Throssell D, McKane WS, et al. Vacuum-assisted closure (VAC) therapy in the management of wound infection following renal transplantation. *Kathmandu Uni Med J* 2007;5(17):4-7
- Rozen WM, Shahbaz S, Morsi A. An improved alternative to vacuum-assisted closure (VAC) as a negative pressure dressing in lower limb split skin grafting: a clinical trial. *J Plast Reconstr Aesthet Surg* 2008; 61(3): 334-7.
- Körber A, Franckson T, Grabbe S, Dissemond J. Vacuum assisted closure device improves the take of mesh grafts in chronic leg ulcer patients. *Dermatol* 2008;216(3):250-6.
- Hanasono MM, Skoracki RJ. Securing skin grafts to microvascular free flaps using the vacuum-assisted closure (VAC) device. *Ann Plast Surg* 2007;58(5):573-6
- Nather A, Hong NY, Lin WK, et al. Effectiveness of bridge V.A.C. dressings in the treatment of diabetic foot ulcers. *Diabetic Foot & Ankle*. 2011;2:5893-96.
- Argenta LC, Morykwas MJ, Marks MW. Vacuum-assisted closure: state of clinic art. *Plast Reconstr Surg* 2006;117(7 Suppl):127S-142S.
- Wong LK, Nesbit RD, Turner LA, Sargent LA. Management of a circumferential lower extremity degloving injury with the use of vacuum-assisted closure. *South Med J* 2006;99:628-30.
- Andrews BT, Smith RB, Goldstein DP, Funk GF. Management of complicated head and neck wounds with vacuum-assisted closure system. *Head Neck* 2006;28:974-81.
- Armstrong DG, Lavery LA. Diabetic foot study consortium. Negative pressure wound therapy after partial diabetic foot amputation: a multicentre, randomised controlled trial. *Lancet* 2005;366: 1704-10.
- Scherer LA, Shiver S, Chang M. The vacuum assisted closure device: a method of securing skin grafts and improving graft survival. *Arch Surg* 2002;137:930-3.
- Hallberg H, Holmstrom H. Vaginal construction with skin grafts and vacuum-assisted closure. *Scand J Plast Reconstr Surg Hand Surg* 2003;37: 97-101.
- Molnar JA, De Franzo AJ, Marks MW. Single-stage approach to skin grafting the exposed skull. *Plast Reconstr Surg* 2000;105:174-7.
- Braakenburg A, Obdeijin MC, Feitz R, van Rooij IA, van Griethuysen AJ, Klinkenbijnl JH, et al. The clinical efficacy and cost effectiveness of the vacuum-assisted closure technique in the management of acute and chronic wounds: a randomized controlled trial. *Plast Reconstr Surg* 2006;118:390-7.
- Vuerstaek JD, Vainas T, Wuite J, Nelemans P, Neumann MH, Veraart JC. State-of-the-art treatment of chronic leg ulcers: a randomized controlled trial comparing vacuum-assisted closure (VAC) with modern wound dressings. *J Vasc Surg* 2006;44: 1029-37.
- Timmers MS, Le Cessie S, Banwell P, Jukema GN. The effects of varying degrees of pressure delivered by negative-pressure wound therapy on skin perfusion. *Ann Plast Surg* 2005;55:665-71.
- Morris GS, Brueilly KE, Hanzelka H. Negative pressure wound therapy achieved by vacuum-assisted closure: evaluating the assumptions. *Ostomy Wound Manage* 2007;53:52-7.
- Demaria RG, Giovannini UM, Téot L, Frapier JM, Albat B. Topical negative pressure therapy. A very useful new method to treat severe infected vascular approaches in the groin. *J Cardiovasc Surg (Torino)* 2003;44:757-61.
- Saxena V, Hwang CW, Huang S, Eichbaum Q, Ingber D, Orgill DP. Vacuum-assisted closure: micro-deformations of wounds and cell proliferation. *Plast Reconstr Surg* 2004;114: 1086-98.
- De Filippo RE, Atala A. Stretch and growth: the molecular and physiologic influences of tissue expansion. *Plast Reconstr Surg* 2002;109:2450-62.
- Trueman P. Health economics and topical negative pressure therapy. In: Calne S, editor. Position document. Denmark: European Wound Management Association 2007;5-9.
- Jones SM, Banwell PE, Shakespeare PG. Advances in wound healing: topical negative pressure therapy. *Postgrad Med J* 2005;81:353-7.