

Radiological Examination of Elbow Joint: An Authentic Tool for Forensic Age Estimation

Muhammad Faheem Ashraf¹, Shams Munir², Tanveer Haider³, Samina Kanwal¹, Uzma Zaheen Anwar⁴ and Abdul Hannan³

ABSTRACT

Objective: To determine the frequency of extent of fusion of epiphysis in the bones of elbow joint (lower ends of humerus and upper ends of radius and ulna).

Study Design: Descriptive observational study

Place and Duration of Study: This study was conducted at the Forensic Medicine and Radiology Departments, Govt. Khawaja Muhammad Safdar Medical College from October 2019 to September 2020.

Materials and Methods: Two hundred patients between aged 13-21 years were selected for this study. X-rays of elbow joint were taken in anteroposterior view to visualize the changes in epiphysis and diaphysis and extent of union. Subjects with fractured, malnourished and congenitally malformed elbow joint were excluded from the study after expert opinion from orthopedic surgeon.

Results: The complete fusion of epiphyses of the bones around elbow joints was observed at age of 19-21 years (Stage 4) in males and at age of 16-18 years (Stage 4) in females. Present study found that union of epiphyses of distal humerus and proximal radius and ulna appear in females earlier than in males.

Conclusion: 100% complete union of elbow joint bones, in male cases is at 19-21 year, and 100% complete union of bones of elbow joint in female cases is at the age of 16-18 years.

Key Words: Age assessment, Epiphyseal fusion, Elbow joints

Citation of article: Ashraf MF, Munir S, Haider T, Kanwal S, Anwar UZ, Hannan A. Radiological Examination of Elbow Joint: An Authentic Tool for Forensic Age Estimation. Med Forum 2021;32(2):93-97.

INTRODUCTION

Age assessment is a critical parameter which is used for the identification of individuals either live or dead, and for medico-legal purposes both in civil and criminal matters.¹ Estimation of age continues to be one of the most challenging aspect of skeleton analysis because of the complexity and individual variation of the aging process. Age of an individual can be assessed by using various methods such as physical examination, dentition, radiological examination, sutures of skull, graying of hair and arcussenils.²

Radiography is utilized extensively as investigational core in forensic and archaeological studies.³ Undoubtedly, one of the accurate methods of estimation of age is radiological survey of ossification status of

various bones.⁴ Furthermore, it is considered to be a reliable guide in different methods of determination of age like appearance of epiphysis and its union with diaphysis.⁵

With increasing the cases of judicial litigation, both criminal and civil, a forensic expert has encounter with multiple issues of age estimation for which he/she has to be dependent mainly on study of different ossification centers activities. The union of epiphysis of different bones of a joint, is a reliable scientific and radiological parameter for accessing age of an individual, which is worldwide accepted by all courts of law.⁶ Skeletal metamorphosis is the conversion of soft, membranous, non-ossified fetal bones into hard and ossified adult bones. The union of distal humerus, proximal radius and ulna occurs at elbow to make first joint of the body to unite.⁸ Multiple ossification centers contribute in the development of a single bone. At different intrauterine ages, number of ossification centers in the bones of body are different for example at 11-12 weeks of IU life, the number of ossification centers is 806 and at birth it remains only 450, while an adult human skeleton only have 206 bones. The appearance of ossification centers and union of epiphysis with diaphysis is highly time framed, which is generally utilized towards determination of age.^{6,9}

Therefore, this study's objective is to determine the frequency of extent of fusion of epiphyses in the bones of elbow joint in declared age group population. The

¹. Department of Forensic Medicine / Radiology² / Orthopedic Surgery³, Govt. Khawaja Muhammad Safdar MC, Sialkot.

⁴. Department of Forensic Medicine, AMC, Lahore.

Correspondence: Dr. Muhammad Faheem Ashraf, Assistant Professor Forensic Medicine, Govt. Khawaja Muhammad Safdar Medical College, Sialkot.

Contact No: 0300-7771362

Email: faheemashraf206@gmail.com

Received: October, 2020

Accepted: December, 2020

Printed: February, 2021

variable of age can be determined accurately with the help of radiographs of elbow joint by visualizing the union of epiphysis and diaphysis between the age of 13 to 21 years.

In a society like Pakistan where forged documents are a problem too, assessment of age by forensic experts is needed. Moreover, we have a certain number of refugees and tribes who do not get them registered for age and their data is quite doubtful. Furthermore, there are many situations other than this like admission in educational institutes, retirement age, maturity, in case of marriages, adoption, guardianship, Govt. jobs, juvenile offenders, age limit for sports events at national and international levels, elections (voters and contestants) which all need age certification. Due to low literacy rate, unawareness, financial problems and shortage/ lack of time, many people do not get their children registered. There is a growing need of accurate method for age estimation in forensic medicine. However, this study is helpful to deal with such cases. The results of this study may help the forensic experts for administration of justice and for the purpose of law.

MATERIALS AND METHODS

This descriptive observational study selected 200 cases between the ages of 13-21 years presented to Radiology Department, Govt. Khawaja Muhammad Safdar Medical College Sialkot from 1st October 2019 to 30th September 2020 for X-ray of elbow joint. Convenience sampling technique was used. X-rays of elbow joint were taken in anteroposterior view to visualize the changes in epiphysis and diaphysis and extent of union. Subjects with fractured, malnourished and congenitally malformed elbow joint were excluded from the study after expert opinion from orthopedic surgeon. The study variables were epiphyseal center appearance and their fusion, age groups in both genders. Status of epiphysis union was divided into four stages. The data was entered and analyzed through SPSS-20.

RESULTS

This study observed 200 subjects including 121 males (60.5%) and 79 females (39.5%) having the age of 13 to 21 years (Fig. 1). Out of 121 male cases, lower ends of humerus fusion (LEHF) was seen in 78 males and in 74 female cases out of 79 subjects). On the other hand, an upper end of radius & ulna fusion (URUF) was observed in 78 male cases out of 121 subjects and URUF was observed in 71 females out of 79 females only (Table 1). Table-2 describes that complete extension of fusion was observed in n=78 cases (including n=10 at the Stage 3 and n=68 at the Stage 4). However, extension of Fusion was seen in 75 out of 79 female subjects at Stage 4. Furthermore, extension of Fusion was observed in n=10 male cases in the age group of 16-18 years and n=68 male subjects in the age

group of 19-21 years whereas, it was observed in 75 female subjects in the age group of 13-15 years as presented in the Table-3.

Table-4 compared the reported age with the estimated age and this comparison found a significant difference between reported age and estimated age as 117 (male=73 and female=44) subjects reported their correct age. The difference between the reported age and estimated age is highly significant with the p-value <.001 out of 0.05. The results expressed the distribution of the subjects according to the reported age and actual age of the subjects. It was found that only n=63 subjects reported their age matching with their actual age and the remaining n=137 reported their age wrong as presented in Table-5.

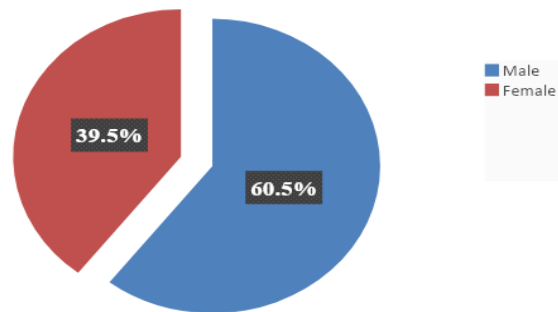


Figure-1: Distribution of gender

Table No.1: Gender-wise frequency of lower ends of humerus and upper ends of radius & ulna fusions

Variable	Gender					
	Male		Female		Total	
	n	%	n	%	n	%
Lower end of HF						
Observed	78	64.5	74	93.7	154	77.0
Not-observed	43	35.5	5	6.3	46	23.0
Upper end of RUF						
Observed	78	64.5	71	90	149	74.5
Not-observed	43	35.5	8	10	51	25.5

Table No.2: Gender-wise frequency of extension of fusion based on stages

Extension of fusion	Gender					
	Male (n=121)		Female (n=79)		Total (N=200)	
	Fused	Not Fused	Fused	Not Fused	n	%
Stage 1	0	41	0	0	41	21
Stage 2	0	2	0	0	2	1
Stage 3	10	0	0	4	14	7
Stage 4	68	0	75	0	143	71

Table No.3: Gender-wise frequency of extension of fusion based on age groups

Estimated age (group years)	Gender					
	Male (n=121)		Female (n=79)		Total (N=200)	
	Fused	Not Fused	Fused	Not Fused	n	%
13-15	0	41	0	4	45	22.5
16-18	10	2	75	0	87	43.5

19-21	68	0	0	0	68	34
-------	----	---	---	---	----	----

Table No.4: Gender-wise comparison of reported age with estimated age

Reported age	Gender					
	Male (n=121)		Female (n=79)		Total	
	n	%	n	%	n	%
Did Match with estimated age	73	60	44	56	117	58.5
Did not match with estimated age	48	40	35	44	83	41.5

Chi-square=58.08, p-value < 0.001

Table No.5: Gender-wise status of reported age by matching with estimated age

Reported Age (years)	Matching status				
	Estimated age matched with reported		Estimated age did not match with reported		Total
	N	%	n	%	n
13	21	22	6	22	27
14	17	19	4	19	21
15	6	67	12	67	18
16	6	63	10	63	16
17	18	44	14	44	32
18	23	38	14	38	37
19	9	47	8	47	17
20	12	37	7	37	19
21	5	62	8	62	13
Total	117	58.5	83	41.5	200

Chi-square=48.24, p-value < 0.001

DISCUSSION

This study compared the reported and estimated age. This comparison found a difference between two as 117 (male=73 and female =44) subjects reported their correct age. The difference between both reported and estimated age is highly significant with the p-value <.001 out of .05. Similarly, Naik and Nagaraja¹⁰ conducted a study with school children and college students with age group of 12 to 18 years. The age estimation in this was found to be equal to the actual age in 24 % of cases. The estimated age was found to be less than the actual age in 24% of cases by 4.5 months of age. Estimated age was found to be more than the actual age in 52% of cases by 8.5 months of age. So the average error in females was 6.5 months than the actual age. In males, the estimated age was found to be equal to the actual age in 40% of cases. The estimated age was found to be less than the actual age in 28% of cases by 7.5 months of age. The estimated age was found to be more than the actual age in 32% of cases by 5.5 months of age. It is interesting to note that

both in the females and males belonging to this age group the range of error in the age estimation is 6.5 months.

This study identified that LEHF was seen in 78 subjects out of 121 male cases whereas in 74 subjects out of 79 female cases. Furthermore, 100% complete union of LEHF was seen in n=68 male cases in the age group of 19-21 years (stage 4). On the other hand, 100% complete union of LEHF was observed in n=74 female cases in the age group of 16-18 years (Stage 4). It was also found that union of LEHF was not observed in 41 male cases at the age group of 13-15 years (stage 1) and only 4 female cases at the same age group and stage 3. It was found that complete union of LEHF appeared in female cases before the male subjects.

In a similar study, Nandanwar et al¹¹ found the age of fusion of composite epiphysis of lower end of humerus by 16-17 years in males and 14-15 years in females. Furthermore, age of union of composite epiphysis of lower end of humerus was almost similar for Europeans by Gray et al.¹² A quite old study conducted in Pakistani region by Ledger and Wasson, 1941¹³ had also reported same age for girls with Nandanwar et al¹¹ but lower in case of boys.

This study found URUF in 78 male subjects out of 121 and in 71 female subjects out of 79 cases. Moreover, 100% complete union of URUF appeared in 68 male cases of the age group of 19-21 years (Stage 4). Whereas, 100% complete union of URUF was observed in 75 female cases of the age group of 16-18 years (Stage 4). It was also observed that union of URUF did not appear in 40 male cases at the age group of 13-15 years (Stage 1) in addition to 2 female cases at the same age group and stage. It was also found that complete union of URUF appeared in females before the male subjects.

In a similar study, Nandanwar et al¹¹ found that upper radial end fused with the shaft between 17 to 18 years in males and 14 to 15 years in females. This age, given by Gray et al¹² for Europeans matched with the present study and report by Ledger and Wasson¹³ for Pakistanis which was also similar to that found in Nandanwar et al.¹¹ Nandanwar et al¹¹ also reviewed that union of upper end of radius and ulna appeared for Europeans is 16-17 years in males and 14-15 years in females.

Study describes that out of 121 male cases, extent of fusion of epiphyses in the bones of elbow joint was observed in 68 cases at Stage 4 for the age group of 19-21 years. Furthermore, the complete extension of fusion was observed in n=68 out of 121 male subjects of the age group of 19-21 years and Stage 4.

Similarly to my study, Nemade et al⁵ performed a study among a total of 320 healthy subjects having ages of 13 to 23 years. Chronological age upto the day of examination was determined and A-P view of right elbow joint was taken in each case. This study determined that complete union of epiphyses in 100%

subjects was observed in male cases at the age of 16 to 17 years. Nandanwar et al¹¹ also found the union of epiphysis during the age of 17-18 years for boys.

Study found that extent of fusion of epiphyses in the bones of elbow joint was seen in 75 out of 79 female cases at Stage 3 for the age group of 16-18 years. Furthermore, the complete extension of fusion was found in 75 females out of 79 at the age group of 16-18 years (Stage 4).

Similarly, the study of Dixit and Bansal¹⁴ found fusion of ossification centers in the upper ends of radius & ulna and lower end of humerus of females. This study discovered fusion of ossification centers found between 15 years to 15.5 years in 92% cases and between 15.5 years to 16 years in 96% cases but all the cases i.e. 100% showed fusion between 16 to 17 years. Jnanesh et al¹⁵ reported that epiphyseal center for medial epicondyle fuses with shaft at the age of 14-15 years in females.

Memchoubi¹⁶ described that all female participants showed their grade 3 elbow joint fusion at the age of 16 years, while Memon et al¹⁷ concluded the grade 3 Ossification of elbow joint bones in female subjects at 14-15 years and same by Dere et al.¹⁸

Bokariya et al¹⁹ reviewed that that in all studies females show earlier fusion than males. Nandanwar et al¹¹ also found the union of epiphysis during this very age of 14-15 years in girls.

Comparing all the studies, it was observed that fusion around elbow are by and large, similar to studies done by Nandanwar et al¹¹, Sangma et al²⁰, Memchoubi¹⁶, Memon et al¹⁷, Singh.²¹ This similarity of age assessment by fusion of elbow joint can be attributed to this study.

The present study found difference in the ages of union of epiphyses for males and females. Similarly, the study of Nandanwar et al¹¹ also reported that epiphyseal union was found to be earlier in females than males.

CONCLUSION

Many participants (n=83) did not report their correct age. Due to this, a significant difference between reported age and estimated age of the subjects was determined with respect to their correct age. It was also identified that 100% complete fusion of elbow joint bones in males take place at the age of 19-21 years and in females it is at 16-18 years, means that fusion of elbow joint bones in females is earlier than in males. Assessment of age through epiphyseal fusion is an economical and reliable tool in Forensic Medicine.

Author's Contribution:

Concept & Design of Study: Muhammad Faheem Ashraf
 Drafting: Shams Munir, Tanveer Haider
 Data Analysis: Samina Kanwal, Uzma

Zaheen Anwar and
 Abdul Hannan
 Muhammad Faheem
 Ashraf, Shams Munir
 Muhammad Faheem
 Ashraf

Revisiting Critically:

Final Approval of version:

Conflict of Interest: The study has no conflict of interest to declare by any author.

REFERENCES

1. Patond S, Tirpude B, Pande V. Age estimation by radiological assessment of proximal tibial epiphysis. *J Med Sci* 2015;8:144-9.
2. Patel DS, Agarwal H, Shah JV. Epiphyseal fusion at lower end of radius and ulna valuable tool for age determination. *J Ind Acad Forensic Med* 2011;33:2.
3. Mughal AM, Hassan N, Ahmed A. Bone age assessment methods: a critical review. *Pak J Med Sci* 2013;30:211-5.
4. Kadam SS, Viswanathan K. Age estimation radiologically from epiphyseal union at wrist joint among subjects in Davanagere District. *Ind J Forensic Med Toxicol* 2012;6:195.
5. Nemade K, Kamdi N, Parchand M. Ages of epiphyseal union around wrist joint—a radiological study. *J Anat Soc Ind* 2010;59: 205-10.
6. Wankhade P, Tirpude B, Khandekar I, Hussaini N, Wankhade S. A roentgenographic study of wrist joint ossification for age estimation in the male population of central India. *J Forensic Med Sci Law* 2013; 22: 1-9.
7. O'connor J, Bogue C, Spence L, Last J. A method to establish the relationship between chronological age and stage of union from radiographic assessment of epiphyseal fusion at the knee: an Irish population study. *J Anat* 2008;212:198-209.
8. Mansourvar M, Ismail MA, Herawan T, Raj RG, Kareem SA, Nasaruddin FH. Automated bone age assessment: motivation, taxonomies, and challenges. *Comput Math Methods Med* 2013;2013:391626.
9. Vij K. Textbook of forensic medicine & toxicology: principles & practice. New Delhi: Elsevier Health Sciences;2014.
10. Naik MS, Nagaraja T. Analytical study of age estimation by the ossification centers around the "elbow joint" in the age group of 12-18 years. *Int J Biol Med Res* 2015; 6: 4722-4.
11. Nandanwar R, Wahane A, Dange N. A roentgenologic study of epiphyseal union around elbow joints in boys and girls of Bastar Region. *Ind J Clin Anat Physiol* 2016; 3:217-29.
12. Gray H, Carter HV, Pick TP, Howden R. Anatomy descriptive and surgical. New York: Fall River Press; 2012.

13. Ledger LK, Wasson TC. Ages of epiphysial union at elbow and wrist joints amongst 238 children in North West Frontier Province. *Ind Med Gaz* 1941;76: 81-4.
14. Dixit SP, Bansal R. Study of ossification centres fusion of elbow joint in 15 to 17 years Garhwali females of Dehradun region. *J Ind Acad Forensic Med* 2014;36: 396-8.
15. Jnanesh R, Thomas S, Gowd H. Estimation of age by roentgenologic study of epiphyseal union at the lower end of humerus in Karnataka. *Anatomica Karnataka* 2011;5:6-10.
16. Memchoubi P. Age determination of Manipuri girls from the radiological study of epiphyseal union around the elbow, knee, wrist joints and pelvis. *J Ind Acad Forensic Med* 2006;28:55-9.
17. Memon N, Memon MU, Memon K, Junejo H, Memon J. Radiological indicators for determination of age of consent and criminal responsibility. *JLUMHS* 2012;11: 64.
18. Dere R, Kukde H, Maiyyar A, Dhoble S. Age determination of female sport persons of age 9–18 years by radiological examination of elbow and wrist joint. *J Forensic Med Sci Law* 2014; 23: 1-6.
19. Bokariya P, Chowdhary D, Tirpude B, Kothari R, Waghmare J, Tarnekar A. A review of the chronology of epiphyseal union in the bones at knee and ankle joint. *J Ind Acad Forensic Med* 2011;33: 258-60.
20. Sangma WBC, Marak FK, Singh MS, Kharrubon B. Age determination in girls of north–eastern region of India. *JIAFM* 2007;29:102-8.
21. Singh TB. Determination of age of majority of Manipuri girls from the radiological examination of the joints. *Medicolegal Update Int J* 2007;7: 41-4.