

Comparison of Two Techniques of Mandible Fracture Fixation Regarding Their Postoperative Complications

Parveen Memon¹, Ghulam Habib², Muhammad Shahzad², Muhammad Rizwan³

ABSTRACT

Objective: The objective of our study was to compare complications of fracture mandible treated by miniplate only and miniplate plus maxilla mandibular fixation (MMF).

Study Design: Comparative Study

Place and Duration of Study: This study was conducted at Liaquat University Hospital Hyderabad from May 2007 to April 2008.

Patients and Methods: This study was conducted on (100) one hundred patients of single mandible fracture. Patients were distributed into two groups (Group A and Group B). Patients in group A fracture, fixation was done by miniplate fixation and patients in group B were managed by miniplate plus MMF for upto 15 days. All patients were followed after surgery for at least two months. Incidence of development of infection, nonunion, malocclusion, nerve damage, TMJ dysfunction and delayed union was evaluated.

Results: Bone union was occurred in all patients. Ten complications were developed in ten patients. In group A number of complications were 8 (16%) and in Group B number of complications were 2 (4%).

Conclusion: Rigid internal fixation in the form of miniplate plus MMF for shorter duration is advantageous as it has good function result and lesser number of complications.

Key Words: fracture mandible, category of treatment, complication

Citation of article: Memon P, Habib G, Shahzad M, Rizwan M. Comparison of Two Techniques of Mandible Fracture Fixation Regarding Their Postoperative Complications. Med Forum 2016;27(12):2-5.

INTRODUCTION

Maxillofacial injuries are the most common types of injuries presenting at emergency departments.¹⁻³ Maxillofacial trauma is main cause of mortality and morbidity worldwide.⁴⁻⁶ Mandible is the single bone of facial skeleton which take part a major action in mastication, speech and deglutition. The most prominent bones of face are mandible and zygomatic bones and both are more vulnerable to trauma and fracture.⁷⁻¹¹ Fracture of these bones may occur alone or in combination with other facial bone fractures.¹²⁻¹⁵ Its fracture may affect its function and cause disfigurement. Pattern of mandibular fractures may be affected by geographic location, social, cultural and environmental factors and social activity.¹⁶⁻¹⁸

Most common cause of mandibular fracture in developing countries is road traffic accidents due to lack of implementation of the traffic laws, while

contrastingly in developed countries alcohol related to interpersonal violence and physical assault is the chief cause of mandibular fracture.¹⁸⁻²²

Treatment of fracture mandible remains a challenge demanding skill and high level of expertise. Fracture mandible can be treated by close or open reduction and fixation.²³⁻²⁷ It has been reported that different complications can occur after close and open reduction and fixation.²⁸⁻³³ Previously close reduction methods were most popular used for mandibular fracture.³⁴⁻³⁶ MMF has many difficulties for patients of preventing normal jaw function, restricting the diet to liquid or semisolid and difficult maintains of oral hygiene. Recently rigid internal fixation has gain popularity in treating fracture mandible by use of miniplates and screws.

Infections, malocclusion, delayed union and even some time nonunion, nerve damage and reduction in ventilatory volume followed by occurrence of pulmonary atelectasis may occur after close and open reduction of fracture are^{26,33}.

MATERIALS AND METHODS

This study was carried out on one hundred patients visited Liaquat University Hospital Hyderabad from May 2007 - April 2008. There were 89 (89%) males and 11 (11%) females. Most common site was para symphysis (50%).

Fractures were treated after the incidence of injury within 72 hours. Patient having single mandibular

¹ Department of Operative Dentistry / Oral and Maxillofacial Surgery² / Prosthodontics³, Institute of Dentistry, Liaquat University of Medical & Health Sciences, Jamshoro, Sindh.

Correspondence: Dr. Ghulam Habib Arain, Lecturer, Department of Oral and Maxillofacial Surgery, Institute of Dentistry, Liaquat University of Medical & Health Sciences, Jamshoro, Sindh.

Contact No: 0333-2606590

Email: drhabib750@gmail.com

Received: September 17, 2016; Accepted: October 29, 2016

fracture, medically fit for surgery and having sufficient dentition to assess occlusion were included in our study. Patients having bone pathology, immune-compromised patient's and patients with comminuted and infected fractures were excluded.

Patients selected by above inclusion and exclusion criteria were distributed into two groups. Patients in group A were treated by Mini plates and patients in group B were treated by mini plates + MMF for up to 15 days. Under general anesthesia intraoral mucosal incision was made in aseptic conditions, fracture was reduced and pretraumatic occlusion was established, miniplates placed & secured with four 2.0 mm wide 7.0 mm long mono cortical screws following Champys principle. Surgical site was irrigated with normal saline, incision closed and antibiotics were given to all patients. Post-operative radiographs were taken. All patients included in the study were followed for at least two months. During follow up patients were examined for post-operative complications. Collected data was analyzed by using SPSS version 17. Chi-square and T-test significance test were used with P-value (P>0.05).

RESULTS

Table No.1: Distribution of Mandible Fracture Site

Site	No. of Patients	%ages
Symphysis	16	16%
Para Symphysis	50	50%
Body	24	24%
Angle	10	10%

Table No.2: Frequency of Complications

Complication	Miniplate	Miniplate + MMF	Total
Infection	8%	4%	12%
Malocclusion	6%	0%	6%
Delayedunion	0%	0%	0%
Non Union	0%	0%	0%
Nerve Damage	2%	0%	2%
TMJ dysfunction	0%	0%	0%
Total	16%	4%	20%

■ Male 90% ■ Female 10%

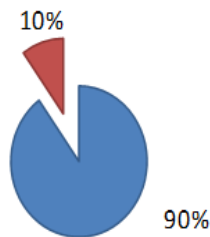


Figure No.1: Distribution of Male and Female

In our study 89% were males patients and 11% were females (figure-1)). Most common age group of the patient was 21-30 years. Most common cause of

mandibular fracture found in our study was Road traffic accidents. Union and bone healing of fractures were achieved in all cases. Ten complications encountered in 10 patients among two groups (100 patients). Distribution of mandibular fracture site is shown in table 1 and details about post-operative complications are given in Table 2.

DISCUSSION

In our study road traffic accident was found common cause of fractures. Young adult males (21-30) years of age were prominent victims. Parasymphysis was found most common site of fracture. The results of epidemiologic surveys on the causes, incidence and distribution of mandibular fracture vary with geographic regions, socio economic conditions and culture characteristics.⁵⁻¹³ The relatively high male to female ratio in our study is due to the fact that males are engaged more in outdoor activities while females are confined to indoor activities in this part of world.

Previous Studies conducted to compare the close reduction by MMF with open reduction and fixation. Cowood³⁷ and Renon³⁸ have also found the rigid Internal Fixation as the treatment of choice.

Several Other studies show the maxillomandibular fixation is superior regarding post-operative complications³⁴⁻³⁶. Recent studies conducted by Belouran³⁹ and Chiritab⁴⁰ used maniplates + MMF for fewer days (1-2 weeks) and found lesser Complications. Result in this study regarding postoperative infection in group A was 8% and in group B was 4% are comparable with that of previous studies done internationally. Infection in miniplate use was found by Demotos²⁶ and Barry⁴¹, 8%, Pazaoa²⁴ 9% and Sauerbier⁴² found 7.5% respectively.

Mobility of fractured segments, placement of screw in the line of fracture, poor plate adaptation and contouring, inadequate cooling during preparation of holes for insertion of screws and tooth in fracture line increases the risk of post-operative infection. Lack of antibiotics used considered to be predisposing factor for infection.

In group A infection was double then group B. It favors that in group B single miniplate was used along with MMF for up to fifteen day has reduced infection rate, possible because of reduction in implanted material minimized procedure errors.

In this study malocclusion Occurred 6% in group A and non of patient in group B faced this complication. Regarding Malocclusion in Group A our results are matching with that of Previous Studies^{19, 22}. Presence of malocclusion depends upon patients' dental condition, number of fractures and their displacement, achieved reduction, kind of Immobilization and the time of immobilization and inappropriate bending and adaptation of plates. This study favors that Miniplate Fixation + MMF for up to two weeks achieves

reduction of fracture that is sufficient to obtain good post-surgical occlusion. Rigidity of osteosynthesis material is an advantage because it allows immediate jaw mobility but it can also be a draw back if it prevents correction of a post-operative malocclusion with MMF. Malocclusion was corrected by occlusal grinding. Group A showed sensory disturbances in 2% of patients that is matching with the study of Schon²³ and is probably due to manipulation of fractured segment in the placement of two miniplates at parasymphysis region. While in group B we used one miniplate and none of patient faced this complication.

CONCLUSION

Rigid internal fixation in the form of miniplate plus maxillomandibular fixation for shorter duration is advantageous as it has good functional results and lesser number of complications.

Conflict of Interest: The study has no conflict of interest to declare by any author.

REFERENCES

1. Paes JV, de SaPaes FL, Valiati R. Retrospective study of prevalence of face fracture in southern Brazil. *Ind J Dent Res* 2012;23:80-86.
2. Ajmal S, Khan MA, Jadoon H, Malik SA. Management protocol of mandible fracture at Pakistan Institute of Medical Sciences Islamabad. *J Ayoub Med Coll* 2007;19(3):51-55.
3. Aksoy E, Unlu E, Sensoz O. A retrospective study on epidemiology and treatment of maxillofacial fractures. *J Craniofac Surg* 2002;13(6):773-777.
4. Erol B, Tanrikulu R, Gorgun B. Maxillofacial fractures. Analysis of demographic distribution and treatment in 2901 patients (25-year experience). *J Craniomaxillofac Surg* 2004;32(3):308-313.
5. Lee JH, Cho BK, Park WJ. A 4-year retrospective study of facial fractures on Jeju, Korea. *J Craniomaxillofac Surg* 2010;38(3):192-196.
6. Gassner R, et al. Cranio-maxillofacial trauma: a 10 year review of 9,543 cases with 21,067 injuries. *J Craniomaxillofac Surg* 2003;31(1):51-61.
7. Van den Bergh B, et al. Aetiology and incidence of maxillofacial trauma in Amsterdam: a retrospective analysis of 579 patients. *J Craniomaxillofac Surg* 2012;40(6):e165-e169.
8. Bakardjiev A, Pechalova P. Maxillofacial fractures in Southern Bulgaria – a retrospective study of 1706 cases. *J Craniomaxillofac Surg* 2007; 35(3): 147-150.
9. Iida S, et al. Retrospective analysis of 1502 patients with facial fractures. *Int J Oral Maxillofac Surg* 2001; 30(4):286-290.
10. Ramli R, et al. A retrospective study of oral and maxillofacial injuries in Seremban Hospital, Malaysia. *Dent Traumatol* 2011;27(2):122-126.
11. Motamedi MH. An assessment of maxillofacial fractures: a 5-year study of 237 patients. *J Oral Maxillofac Surg* 2003; 61(1):61-64.
12. Ceallaigh PO, et al. Diagnosis and management of common maxillofacial injuries in the emergency department. Part 1: advanced trauma life support. *Emerg Med J* 2006;23(10):796-797.
13. Mohajerani SH, Asghari S. Pattern of mid-facial fractures in Tehran, Iran. *Dent Traumatol* 2011; 27(2):131-134.
14. Al Ahmed HE, et al. The pattern of maxillofacial fractures in Sharjah, United Arab Emirates: a review of 230 cases. *Oral Surg Oral Med Oral Pathol Oral Radiol Endod* 2004;98(2):166-170.
15. Klenk G, Kovacs A. Etiology and patterns of facial fractures in the United Arab Emirates. *J Craniofac Surg* 2003;14(1):78-84.
16. Mouzakes J, et al. The impact of airbags and seat belts on the incidence and severity of maxillofacial injuries in automobile accidents in New York State. *Arch Otolaryngol Head Neck Surg* 2001; 127(10):1189-1193.
17. Naveen Shankar A, et al. The pattern of the maxillofacial fractures – a multicentre retrospective study. *J Craniomaxillofac Surg* 2012;40(8): 675-679.
18. Gomes PP, Passeri LA, Barbosa JR. A 5-year retrospective study of zygomatico-orbital complex and zygomatic arch fractures in Sao Paulo State, Brazil. *J Oral Maxillofac Surg* 2006;64(1):63-67.
19. Allareddy V, Nalliah RP. Epidemiology of facial fracture injuries. *J Oral Maxillofac Surg* 2011; 69(10):2613-2618.
20. Zargar M, et al. Epidemiology study of facial injuries during a 13 month of trauma registry in Tehran. *Indian J Med Sci* 2004;58(3):109-114.
21. Gandhi S, et al. Pattern of maxillofacial fractures at a tertiary hospital in northern India: a 4-year retrospective study of 718 patients. *Dent Traumatol* 2011;27(4):257-262.
22. Telfer MR, Jones GM, Shepherd JP. Trends in the aetiology of maxillofacial fractures in the United Kingdom (1977-1987). *Br J Oral Maxillofac Surg* 1991;29(4):250-255.
23. Muhammad JA. Management of Mandibular Fracture in Leady Reading Hospital Peshawar *JPGMI* 2005; 19:396-99
24. Paza OA, Abuabara A, Passeri LA. Analysis of 115 Mandibular Angle Fractures. *J Oral Maxillofac Surg* 2008; 66:73-77.
25. Laughlin MR, block SM, et al. Resorbable plates for the fixation of mandibular fractures A prospective study. *J Oral Maxillofac Surg* 2007; 65:89-96.
26. Dematos FP, Arnez MFM. A retrospective study of mandibular fractures in a 40-months period. *Int J Oral Maxillofac Surg* 2010; 39:10-15

27. Moreno JC, Fernandez A, Ortiz JA. Complication rates associated with different treatment for mandibular fractures. *J Oral Maxillofac Surg* 2000; 58: 273-81.
28. Schortinghuis J, Bos RR, Vissik A. Complication of internal fixation of maxillofacial fractures with microplates. *J Oral Maxillofac Surg* 1999;57: 130-34.
29. Farnad FA. Effect of Maxillomandibular Fixation on the Incidence of Postoperative pulmonary Atelectasis. *J Oral Maxillofac Surg* 2002;60: 988-90.
30. Rotlern HU, Sporre B: Airway closure, atelectasis and gas exchange during general anaesthesia. *Br J Anesth* 1998;81:681.
31. Johanson WG, Peter H. Complications and Philosophy, *Respiratory Medicine*, 2nd ed. Philadelphia: PA Saunders; 1994.p.2035-2037.
32. Manor Y, Chaushu G, Taicher S. Risk factors contributing to symptomatic plate removal Orthognathic surgery patients. *J Oral Maxillofac Surg* 1999;57: 679-82.
33. Orringer JS, Barcelona V, Buchman SR. Reasons for removal of rigid internal fixation devices in Craniofacial surgery. *J Craniofac Surg* 1998;9(1): 40-44.
34. Lamphier J, Zicardi V, Ruvo, Janel M. complication of mandibular fractures in an urban teaching center. *J Oral Maxillofac Surg* 2003; 61: 745-50.
35. Moulton BR, Rubinstein AJ, Salzhauer MA, Brown M, Angulo J, Alster C, et al. Complication of mandibular fractures. *Ann Plast Surg* 1998;41: 258-63
36. Leach J, Truelson J. Traditional methods Vs rigid internal fixation of mandible fracture. *Arch Otolaryngol Head Neck Surg* 1995;121: 750-57.
37. Cawood JL. Small plate osteosynthesis of mandibular fractures. *Br J Oral Maxillofac Surg* 1985;23;77-91.
38. Renton TF, Wiesenfeld D. Mandibular fractured osteosynthesis: a comparison of three techniques. *Br J Oral Maxilloface Surg* 1996; 34: 166-73.
39. BolourianR, miniplates fixation of mandibular fractures plus 2 weeks' Maxillomandibular fixation. *J Oral Maxillofac Surg* 2002;60:167-70.
40. Chritab A, Stewerk K. Transoral 2.0-mm locking Miniplate Fixation of Mandibular Fractures Plus 1 Week of Maxiillomandibular Fixation. *J Oral Maxillofac Surg* 2005;63: 1737-1741,
41. Berry CP, Kearns G. Superior Border Plating Technique in the Management of isolated Mandibular Angle Fractures: A Retrospective Study of 50 Consecutive Patients. *J Oral Maxillofac Surg* 2007; 65:1544-49.
42. Saverbier S, Kuinz J, Clinical aspect of 2.0-mm locking plate system for mandibular fracture surgery. *J Cranio Maxillofac Surg* 2010;38:501-04.
43. Shown R, Roveda SIL, et al. mandibular fractures Townsville, Australia: inclusion, aetiology and treatment using the 2.0 AO\ asif miniplate system. *Br J Oral Maxillofac Surg* 2001;39:145-48.

Electronic Copy