

# Assessment of Diagnostic Laproscopy in Chronic Abdominal Pain at Tertiary Care Hospital

Farkhanda Jabeen Dahri<sup>1</sup>, Abdul Hakeem Jamali<sup>1</sup> and Qambar Ali Laghari<sup>2</sup>

## ABSTRACT

**Objective:** The objective of this study was to find out the diagnosis of diagnostic laparoscopy in patients having chronic abdominal pain.

**Study Design:** Descriptive / cross sectional study

**Place and Duration of Study:** This study was conducted at the Surgery Department of PMC hospital and PUMHS Nawabshah from February 2014 to March 2015.

**Materials and Methods:** All the undiagnosed cases of chronic abdominal pain (by conventional methods and investigations such as clinical examination, urine examination, US abdomen etc), abdominal pain more than 3 months, cases age more than 18 years either gender and clinically diagnosed as chronic were selected in this study, while all the cases with known cause of pain, Acute inflammatory disease, cases having acute intestinal obstruction, coagulation abnormalities, critical illness, severe/decompensated cardiopulmonary failure and medically unfit for anaesthesia and surgery were not selected in this study. Diagnostic laparoscopy was performed in all selected cases and findings were entered in proforma.

**Results:** Total 45 patients underwent diagnostic laparoscopy majority of the young patients was found. Female were found in the majority 60% as compare to males 40%. 13 (28.88%) patients had pain in right iliac fossa, 08 (17.78%) patients had hypogastrium pain, 10 (22.22%) cases were found with whole abdominal pain, 10 (22.22%) patients had pain in left iliac fossa and 04 (8.89%) patients were noted with pain at right hypochondrium. According to laparoscopy findings, appendicitis and adhesions were most common 14(31.11%) and 10(22.22%) respectively, following by Abdominal tuberculosis, Hernia, Mesenteric lymphadenopathy, Ovarian cyst and Dense adhesions + Thickened gall bladder wall with percentage of 06(13.33), 03(6.67%), 02(4.44%), 04(8.89%) and 02(4.44%) respectively, while 04(8.88%) cases were noted without any disease.

**Conclusion:** Diagnostic laparoscopy in good tool for diagnosis of chronic abdominal pain, according to the assessment the commonest basis of chronic recurrent abdominal pain in this study was appendicitis followed by abdominal tuberculosis and adhesions.

**Key Words:** Laparoscopy, Chronic Pain In Abdomen, Diagnosis

**Citation of article:** Dahri FJ, Jamali AH, Laghari QA. Assessment of Diagnostic Laproscopy in Chronic Abdominal Pain at Tertiary Care Hospital. Med Forum 2016;27(9):37-40.

## INTRODUCTION

Chronic pain in abdomen is the most common presentation, in common surgical procedures. Despite being exposed to many tests, nearly 40% of cases remain undetected at last.<sup>1,2</sup> Long lasting abdominal pain is correlated with low standard of life and considerable levels of distressing indications.<sup>3</sup> The commonest organic stipulations contain intestinal adhesions,<sup>4,5</sup> particularly in cases with a surgical history of abdomen, abdominal TB,<sup>6</sup> biliary basis, appendicular

pathology, mesenteric lymphadenopathy (can as well be because of contagious causes of bowel for example gastroenteritis, colitis or enteric fever despite TB), as well as hernia. Whereas, functional stipulations comprise irritable bowel disorder, FD, as well as a variety of motility diseases. Pain in abdominal wall is as well common and recurrently confused with visceral pain.<sup>7</sup> It is a secure and useful tool that can set up the cause and permits for suitable intercessions. Pain in abdominal is a frequent complaint of admitted cases. Farther than these 25% cases have indistinguishable pain in abdomen.<sup>8</sup> In chronic pain in abdomen above 40% of the cases have no exact etiological diagnosis executed finally at diagnostic workup.<sup>9</sup> Several functional & organic disorders can result in abdominal pain.

Laparoscopic surgery is a method which visualizes peritoneal cavity without any large surgical incisions.<sup>10</sup> It has altered the administration of several surgical disorders.<sup>11</sup> At present diagnostic laparoscopy is established as the ideal prime approach to numerous

<sup>1</sup>. Department of Surgery, PMC Hospital and PUMHS Nawabshah

<sup>2</sup>. Department of Surgery, Liaquat University Hospital Hyderabad

Correspondence: Dr. Abdul Hakeem Jamali, Senior Registrar of Surgery Unit III, PMC Hospital and PUMHS Nawabshah  
Contact No: 0333-2700192

Email: dr.saeedarain786@gmail.com

disorder processes. As diagnostic modality, Laparoscopy is valuable in 3<sup>rd</sup> world nations such as Pakistan due to its maximum yield as well as higher economy as contrasted to further examinations such as MRI & CT scan.<sup>12</sup> It permits quick revisit to a regular diet as well as every day activity, exhibits better cosmetic outcomes, is less expensive as contrasted with imaging studies, prevents needless laparotomy as well as can possibly present treatment simultaneously. Although, at first, laparoscopy was believed to be contentious in unjustified abdominal pain because of causal adhesions risk. However, today it is measured as well- recognized as well as proficient means of not just in evaluating every organ in abdomen although surgeons are getting expert in numerous therapeutic methods together with adhesionolysis.<sup>13</sup> The objective of this study was to detect the assessment of diagnostic laparoscopy in cases with recurrent pain in abdomen.

**MATERIALS AND METHODS**

This cross sectional study was held at the surgery department of PMC hospital and PUMHS Nawabshah. All the patients of undiagnosed (by conventional methods and investigations such as detailed history, clinical examination, blood counts, urine examination, USG abdomen, plain x-ray abdomen) chronic pain in abdomen for above 3 months of duration in patients of more than 18 years of age, and cases of clinically diagnosed chronic pain in abdomen for above 3 months of duration, non-respondent to the treatment given were incorporated in the study. While cases with identifiable process that can explain the cause of pain Acute or inflammatory process, Patients with acute intestinal obstruction, and Patients with coagulation defects, critical illness, severe/ decompensated cardiopulmonary failure and medically unfit for surgery were excluded from the study. Detail history was taken and examination was carried out and after necessary investigations, diagnostic laparoscopy was done to expose the cause of chronic pain in abdomen and findings were recorded on pre-designed proforma. All data was analyzed on SPSS version 19.

**RESULTS**

Total 45 patients underwent diagnostic laparoscopy majority of the young patients was found as: 16(35.56%) cases were found with 18-30 yrs of age group; while 16(17.77%) patients were between 31-40 years, and 18(20%) patients were with 41-50 years of age group. Table 1

In this series female were found in the majority 60% as compare to males 40%. Figure 1

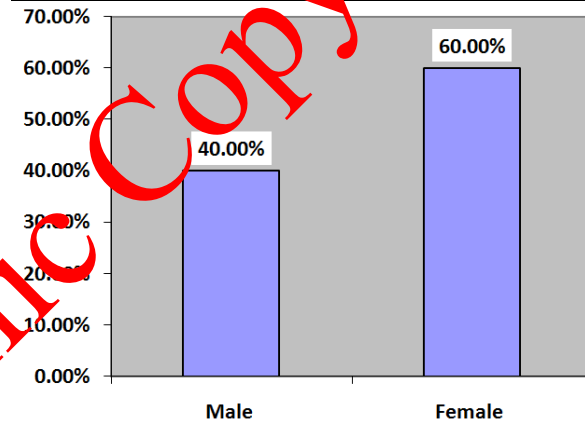
According to the site of pain, 13 (28.88%) patients had pain in right iliac fossa, 08 (17.78%) patients had pain in hypogastrium, 10 (22.22%) cases were found with whole abdominal pain, 10 (22.22%) patients had pain in

left iliac fossa and 04 (8.89%) patients were noted with pain at right hypochondrium. Table 2

According to laparoscopy findings, appendicitis and adhesions were most common 14(31.11%) and 10(22.22%) respectively, following by Abdominal tuberculosis, Hernia, Mesenteric lymphadenopathy, Ovarian cyst and Dense adhesions + Thickened gall bladder wall with percentage of 06(13.33%), 03(6.67%), 02(4.44%), 04(8.89%) and 02(4.44%) respectively, while 04(8.88%) cases were noted without any disease. Table 3.

**Table No.1: Age distribution of the patients (n=45)**

Age	No. of patients / (%)
Age group (in years)	
18-30	16(35.56%)
31-40	09(20.0%)
41-50	09(20.0%)
51-60	7(15.56%)
above 60	4(08.88%)



**Figure No.1: Gender distribution of the cases n= 45**

**Table No.2: Site of Abdominal Pain (N=45)**

Site of Abdominal Pain	No of Patients/%
Right iliac fossa	13 (28.88%)
Hypogastrium	08 (17.78%)
Left iliac fossa	07 (15.56%)
whole abdomen	10 (22.22%)
Right hypochondrium	04 (8.89%)
Umbilical region	03 (6.67%)

**Table No.3: Laparoscopic findings (N= 45)**

Clinical presentation	No of patients/%
Appendicitis	14(31.11%)
Adhesion	10(22.22%)
Abdominal tuberculosis	06(13.33%)
Hernia	03(6.67%)
Mesenteric lymphadenopathy	02(4.44%)
Ovarian cyst	04(8.89%)
Dense adhesions + Thickened gall bladder wall	02(4.44%)
Normal	04(8.88%)

## DISCUSSION

In a number of cases in spite of the entire scheduled laboratory examinations and US cases were not diagnosed. The abdominal disorder is complicated and for investigative diagnosis, patients generally experience diagnostic laparotomy. In such circumstances, investigative laparoscopy is a good option. By this technique can visualize the cavity of abdomen directly, supply sufficient stuff for histopathological evaluation.

In this series young cases were most common and female were found in the majority, while according to the site of pain 13 (28.88%) patients had pain in right iliac fossa, 08 (17.78%) patients had pain in hypogastrium, 10 (22.22%) cases were found with whole abdominal pain, 10 (22.22%) patients had pain in left iliac fossa and 04 (8.89%) patients were noted with pain at right hypochondrium. Similarly Kumar Baria KA et al<sup>14</sup> reported that pain in right lower quadrant was in 50% cases, right upper quadrant 8%, left lower quadrant 2% and periumbilical in 40%, furthermore Kumar Baria KA reported mean age 36 years and female gender most common. Literature review exhibits a range of results of investigative laparoscopy to sustain its application in recurring indistinguishable pain in abdomen. In a few studies above 90% exactness has been reported<sup>15</sup> in diagnosing abdominal pain. In this study, the main cause of chronic pain in abdomen was found to be appendicitis. In our study 14(31.11%) patients had chronic appendicitis was the most common cause chronic pain in abdomen in lower right quadrant. Cause and symptoms of the present study were similar as observed in study of Baria.<sup>16</sup> Reem Al-Bareeq reported In a study that inflamed appendix was observed within 73% patients, while in one more study it was established within 39% cases.<sup>17</sup> In one of the largest series Silky et al<sup>18</sup> was able to identify pathology in 69 out of 70 patients with either appendicitis or gynaecologic pathology being the main finding. These were greater as contrasted to our study, establishing inflamed appendix cases.

Abdominal TB is widespread in our nation; frequently it has no specific characteristics, clinical features, history and indefinite base line examinations and abdominal U/S. Laparoscopy has turn out to be the examination of preference in such patients causing rapid diagnosis and confirmation-based commencement of anti-TB medications.<sup>19</sup> In our study, abdominal tuberculosis was seen in 06(13.33%) patients, which is similar to study conducted by Hossain et al<sup>20</sup>.

In this study, adhesions were found to be source of chronic abdominal pain among 10(22.22%) cases. A few authors, who disprove its significance in adhesiolysis as well as consider it contentious and not proof-based, yet argue the laparoscopic contribution in chronic pain of abdomen. Thus, they do not advise it as

a therapy of adhesion in cases with chronic pain of abdomen.<sup>21</sup> Easter et al<sup>22</sup> had 47% positivity with adhesions being the main finding. Investigative laparoscopy makes it likely for the professionals of surgical procedure to visualize superficial anatomy of abdominal organs in details superior as compare to further imaging modality. Nonetheless, laparoscopy has limitations for instance non-visualization of profound parenchymatous organs, procedures of retroperitoneal cavity as well as the internal surface of unfilled organs, and not permitting the professional of surgery to palpate organs.

## CONCLUSION

In the conclusion of this study the diagnostic laparoscopy in good tool for diagnosis of chronic abdominal pain in those are undiagnosed on conventional methods of investigations, according to the assessment the commonest basis of chronic recurrent abdominal pain in this study was appendicitis followed by abdominal tuberculosis and adhesions. It should be done as soon as possible to prevent the morbidity and mortality.

**Conflict of Interest:** The study has no conflict of interest to declare by any author.

## REFERENCES

1. Townsend CO, Sletten CD, Bruce BK, Rome JD, Luedtke CA, Hodgson JE. Physical and emotional functioning of adult patients with chronic abdominal pain: Comparison with patients with chronic back pain. *J Pain* 2005;6:75-83.
2. Paajanen H, Julkunen K, Waris H. Laparoscopy in chronic abdominal pain: A prospective nonrandomized long-term follow-up study. *J ClinGastroenterol* 2005;39:110-4.
3. Magni G, Rossi MR, Rigatti-Luchini S, Merskey H. Chronic abdominal pain and depression. Epidemiologic findings in the United States. Hispanic health and nutrition examination survey. *Pain* 1992;49:77-85.
4. Peters AA, Van den Tillaart SA. The difficult patient in gastroenterology: Chronic pelvic pain, adhesions, and sub occlusive episodes. *Best Pract Res ClinGastroenterol* 2007;21:445-63.
5. van Goor H. Consequences and complications of peritoneal adhesions. *Colorectal Dis* 2007;9:25-34.
6. Arya PK, Gaur KJ. Laparoscopy: A tool in the diagnosis of lower abdominal pain. *Indian J Surg* 2004;66:216-20
7. Lindsetmo RO, Stulberg J. Chronic abdominal wall pain – A diagnostic challenge for the surgeon. *Am J Surg* 2009;198:129-34.
8. Kamin RA, Nowicki TA, Courtney DS, Powers RD. Pearls and pitfalls in the emergency

- department evaluation of abdominal pain. *Emerg Med Clin N Am* 2003;21:61-72.
9. El-labban GM, Hokkam EN. The efficacy of laparoscopy in the diagnosis and management of chronic abdominal pain. *J Minim Access Surg* 2010;6:95-9.
  10. All sold out Internet Solution: Laparoscopy. [online] 1995-2001. Available from URL: <http://www.healthnmore.org/lapros.htm>.
  11. Yousaf M, Hosuy MA. Small bowel obstruction after laparoscopic inguinal hernia repair. *J Coll Physicians Surg Pak* 2001;11:721-2.
  12. Saeed M, Ayyaz M, Cheema MA (2003). Role of laparoscopy- a diagnostic aid, its indication and benefits. *Ann King Ed Med Coll* 2003;9:232-4.
  13. El-Labban GM, Hokkam EN. The efficacy of laparoscopy in the diagnosis and management of chronic abdominal pain. *J Minim Access Surg* 2010;6(4):95-9.
  14. Kumar Baria KA. Role of laparoscopy in diagnosis and management of chronic Abdominal pain. *Ind J Sci Res* 2013; 4(1) : 65-68
  15. Dominguez LC, Sanabria A, Vega V, Osorio C. Early laparoscopy for evaluation of nonspecific abdominal pain: a critical appraisal of the evidence. *Surg Endosc* 2011;25:10-8.
  16. Baria KAK. Role of laparoscopy in diagnosis and management of chronic Abdominal pain. *Ind J Sci Res* 2013;4(1):65-8.
  17. Al-Bareeq R, Dayna KB. Diagnostic laparoscopy in acute abdominal pain: 5-year retrospective series. *Bahrain Med Bull* 2007;29:1-5.
  18. Salky B. Diagnostic Laparoscopy. *Surg Laparosc & Endosc* 1993;3:132-4.
  19. Chahed J, Mekki M, Mansour A, Ben Brahim M, Maazoun K, Hidouri S, et al. Contribution of laparoscopy in the abdominal tuberculosis diagnosis: retrospective study of about 11 cases. *PediatrSurgInt* 2010;26(4):413-8.
  20. Hossain J, Aska AK, Mofleh I. Laparoscopy in tuberculous peritonitis. *J R Soc Med* 1992;85: 289-91.
  21. Swank DJ, Swank-Bordewijk SC, Hop WC, van Erp WF, Janssen IM, Bonjer HJ, et al. Laparoscopic adhesiolysis in patients with chronic abdominal pain: A blinded randomised controlled multi-centre trial. *Lancet* 2003;361:1247-51.
  22. Easter DW, Cuschieri A, Nathanson LK, Lavelle-Jones M. The Utility of Diagnostic Laparoscopy for Abdominal Disorders: Audit of 120 Patients. *Arch Surg* 1992;127:379-83.

Electronic Copy