

# Effects of Caffeinated Carbonated Soft Drinks on the Testicular Anatomy in Wistar Albino Rat Model

Shoukat Ali Memon<sup>1</sup>, Sajjad Ali Almani<sup>1</sup> and Aftab Ahmed Shaikh<sup>2</sup>

## ABSTRACT

**Objective:** To investigate the effects of caffeinated and non-caffeinated carbonated soft drinks on the testicular anatomy and histology in Wistar albino rat model.

**Study Design:** Experimental study

**Place and Duration of Study:** This study was conducted at the Department of Anatomy, Faculty of Medicine and Allied Medical Sciences, Isra University Hyderabad from July 2014 to February 2015.

**Materials and Methods:** Twenty rats of Wistar albino strain were divided randomly in two groups. Group A were control rats and group B were experimental rats. Caffeinated carbonated soft drinks were given freely to the group B experimental rats. The animals were sacrificed and testes were retrieved for histological examination. The software SPSS 22.0 analyzed the data at P-value  $\leq 0.05$ .

**Results:** Size and weight of rat testes were decreased in caffeinated soft drunk rats ( $P=0.0006$ ) while body weight was increased. Histological examination shows testicular tissue damage in form of necrotic and edematous tissue, hyalinization, tubular luminal defects, and pyknotic nuclei. Seminiferous tubules showed gross microscopic defects.

**Conclusion:** The caffeinated carbonated soft drinks exerts toxic effects on the body weight, testicular size, testicular weight, GSI, seminiferous tubule epithelial cell layers and seminiferous tubular diameter an in-vivo rat model.

**Key Words:** Testes, Carbonated Soft Drinks, Caffeine Rat

**Citation of article:** Memon SA, Almani SA, Shaikh AA. Effects of Caffeinated Carbonated Soft Drinks on the Testicular Anatomy in Wistar Albino Rat Model. Med Forum 2017;28(5):2-6.

## INTRODUCTION

Caffeine is a potent brain stimulant agent. It is a methylated xanthine compound. It is being used in the soft drinks for more than a century. Caffeine is a commonly used psychoactive agent. It is used in the manufacturing of drugs by pharmaceutical industry, but also used in chocolates, energizers, milk coffees and soft drink beverages.<sup>1</sup> Being xanthine; it belongs to purine class of compounds which are involved in the biosynthesis of nucleic acids. Caffeine is derived from the seeds of Coffea plants which is rich source. Caffeinated carbonated soft drinks are used for taste, and for the vigor and vitality. These soft drinks have become part of social cultures throughout the World. These soft drinks increase the physical performance and decrease the drowsiness. A symbol of social status and taste, these soft drinks are consumed by 90% of Americans daily, hence the most popular drink ever used.<sup>2,3</sup> These caffeinated soft drinks contain many agents including sugar, which is in large concentrations.

Hence these soft drinks increase the body weight. Increased body weight is termed as obesity which is a major threat to the public health through its predisposition to cardiovascular diseases. There use has been linked to the obesity and infertility.<sup>4</sup> The recipe of caffeinated soft drinks is serious secret of the soft drink industry which is not known. However, the ingredients mentioned on the labels of the soft drinks show they contain colorants, odorants, flavoring agents, bicarbonate, phosphoric acid, caffeine and sugar.<sup>5</sup> Use of these soft drinks has been prohibited by law in the many states of the America. Its use in School and University students is not allowed by law in the Philadelphia, Los-Angeles and Miami. Soft drinks were banned by California government through a resolution in 2016 declaring as they are harmful for health.<sup>6</sup> Caffeine is inhibitor of Phosphodiesterase (PDE) enzyme which regulates the intracellular c-AMP levels. The c-AMP mediates cellular responses which result in awakening, vigor, vitality, nerve stimulation and physical activity<sup>7-9</sup>. The Gonadosomatic index, (GSI) is a calculated index of percentage of testicular (gonad) weight and the body weight. GSI is a reliable marker of identifying the fertility behavior.<sup>10,11</sup> Recent studies reported the GSI is a reliable indicator of gonadal maturity and fertility in fish model.<sup>11,12</sup> Keeping in view the health hazards of caffeinated carbonated soft drinks and literature review as above, created an interesting concept of conducting on the topic which is current and of public health importance. As the effects of

<sup>1</sup>. Department of Anatomy, Isra University, Hyderabad.

<sup>2</sup>. Department of Pharmacology, Al-Tibri Medical College, Isra University, Karachi Campus.

Correspondence: Dr. Shoukat Ali Memon, Assistant Professor of Medicine, Isra University, Hyderabad, Sindh.

Contact No: 0300-3032792

Email: Giggly786@gmail.com

caffeinated carbonated soft drinks on the testicular may results in fertility problems, hence it was worth to conduct an experimental in-vivo study in Wistar male rats at our animal house to prove the harmful effects scientifically. The present study was conducted to analyze the effects of caffeinated carbonated soft drinks on the testicular size, testicular weight, GSI, seminiferous tubule epithelial cell layers and seminiferous tubular diameter.

## MATERIALS AND METHODS

The present experimental rat study took place at the Department of Anatomy Isra University Hyderabad and Animal house, Sindh Agriculture University, Tando Jam, Sindh. Twenty rats were selected randomly. Rats of body weight 200 grams and age eight to twelve weeks was included. The animal house is well equipped and well ventilated for housing of animals. The Guidelines for Care and Use of Laboratory Animals as per NIH (National Institutes of Health) were followed. Rats were housed in stainless steel cages. Stainless steel vessels are used for feeding of chow. Cages are equipped with "plastic drinkers with nozzles" for the water drinking. Pure clean water was available 24 hours. Access to the chow was limitless. Chow was put in the stainless steel containers which were cleansed and changed daily basis. Healthy environment was ensured by free ventilation, maintenance of hygiene and temperature maintained at 22- 25°C. Light and dark cycles of 12/12 hours were maintained for the animals. Experiment took six months. Twenty rats were divided into 2 groups. Group A – comprised of ten rats and used as control rats. Experimental group B – comprises of 10 rats used for the research purpose. These were drunk on caffeinated carbonated soft drinks. Written research proposal was submitted to the ethical review committee for the animal research and got written permission. GSI (Gonadosomatic index) was estimated as  $[\text{Testis Weight} / \text{Somatic Weight}] \times 100$ .<sup>12</sup> Electronic weighing scale was used for recording body weight measurement at baseline and at the end of experiment period. Caffeinated carbonated soft drinks were given to experimental group B for thirty days. After 30 days, the rats were killed by cervical dislocation. Body cavity was dissected after midline abdominal incision. Testes were traced by blunt and fine dissection as per need. Testes were weighed in electronic balance, and examined grossly. Testes were preserved in formalin container. Microtome was used for cutting 3-5 $\mu$  thick tissue sections. Hematoxylin and Eosin (H & E) staining was used for tissue staining for microscopic examination. SPSS version 22.0 (IBM, incorporation, USA) for windows was used for the analysis of data variables. Continuous variables (analyzed by Student t-test) were presented as mean  $\pm$  SD. All data analysis was performed at 95% confidence interval (P-value  $\leq$  0.05).

## RESULTS

Body weight of controls and experimental rats show statistically significant differences in experimental rats only ( $p=0.0380$ ) as shown in Table -1. The control rats showed no body weight difference at baseline and at the end of experimental period ( $p=0.0910$ ). The testicular size, testicular weight, GSI, seminiferous tubule epithelial cell layers and seminiferous tubular diameter are shown in the table 2-6. The Experimental group rats receiving caffeinated soft drinks showed detrimental effects on the testicular size, testicular weight, GSI, seminiferous tubule epithelial cell layers and seminiferous tubular diameter ( $p<0.05$ ). All of testicular gross anatomical features and histological features were disturbed in the experimental rats drunk caffeinated carbonated soft drinks. Seminiferous tubule epithelial cells layers were decreased in experimental rats along with reduction in GSH, Testicular size and weight and seminiferous tubule diameter. Seminiferous tubules showed loss of tissue architecture, necrosis and Low sperm in the experimental group (Photomicrograph 2). Few layers of germinal epithelium, maturation arrest of spermatogonia and BM is thin with few sperms with edematous interstitial tissue (Photomicrograph 3). Seminiferous tubule hyalinization, decreased germinal layer, edematous and narrowing of lumen were observed in the experimental group (Photomicrograph 4).

**Table No.1: Body weight of Albino rats (grams)**

Groups	Baseline	Final	t-value	P-value
Group A. control rats	218.80	226.40	3.19	0.0910
Group B. Experimental rats	221.20	236.90	5.01	0.0380

**Table No.2: Size of the testes in control and Experimental groups**

Groups	Mean	S.D	t-value	P-value
Group A. control rats	1.85	0.04	17.2	0.0006
Group B. Experimental rats	1.75	0.07		

**Table No.3: Weight of the testes in control and experimental groups in grams**

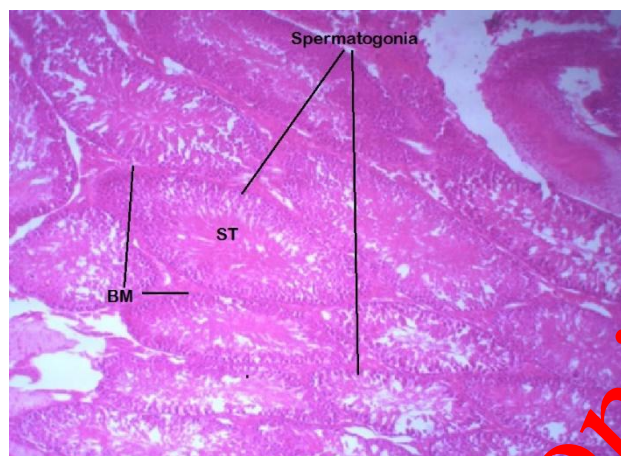
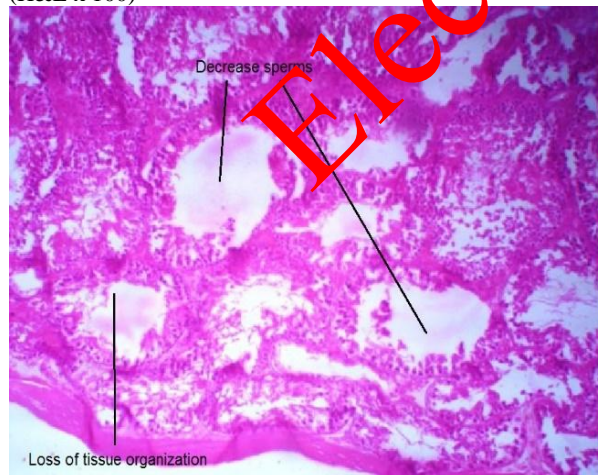
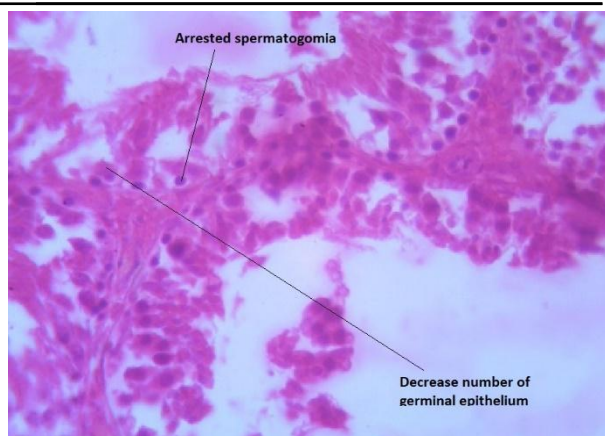
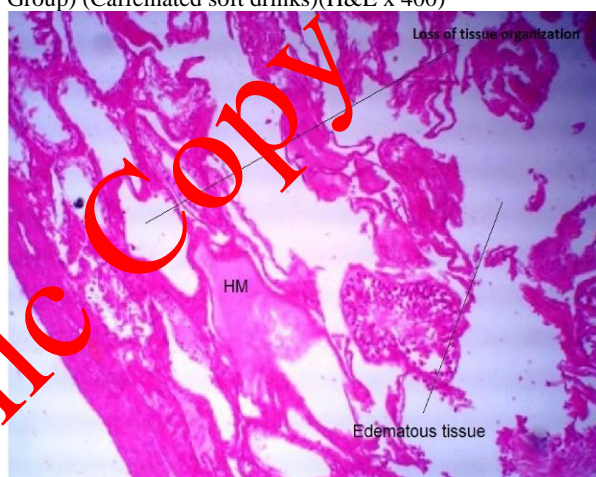Groups	Mean	S.D	t-value	P-value
Group A. control rats	1.07	0.03	92.8	0.0001
Group B. Experimental rats	0.86	0.06		

**Table No.4: Gonadosomatic index (GSI)**

Groups	Mean	S.D	t-value	P-value
Group A. control rats	0.47	0.02	74.7	0.0001
Group B. Experimental rats	0.37	0.04		

**Table No.5: Seminiferous tubule epithelial cell layers**

Groups	Mean	S.D	t-value	P-value
Group A. control rats	5.20	0.63	73.2	0.0001
Group B. Experimental rats	2.90	0.57		

**Photograph-1:** Cross section of seminiferous tubule (ST) of control group shows normal Dark staining nuclei of spermatogonia. Basement membrane (BM) and spermatids are present in luminal surface. Lumens are filled with sperms. (H&E x 100)**Photograph-2:** Seminiferous tubules show loss of tissue architecture, necrosis and Low sperm counts in the experimental group (Caffeinated soft drinks). (H&E x 100)**Photograph-3:** Seminiferous tubule shows few layers of germinal epithelium and maturation arrest of spermatogonia. BM is thin with few sperms. Edema is present. (Experimental Group) (Caffeinated soft drinks) (H&E x 400)**Photograph-4:** Cross section of seminiferous tubule shows hyalinization and maturation arrest of spermatogonia. BM is thin with decreased germinal layer. Edematous and narrowing of lumen were observed in the experimental group (Caffeinated soft drinks). (H&E x 400)**Table No.6: Seminiferous tubules diameter (STD) of rat testes (µm)**

Groups	Mean	S.D	t-value	P-value
Group A. control rats	259.80	4.01	49.1	0.0001
Group B. Experimental rats	257.20	3.97		

## DISCUSSION

The present is the original research study being reported from Department of Anatomy, Isra University. The present experimental study aimed to detect the effects of caffeinated carbonated soft drinks on the body weight, testicular size, testicular weight, GSI, seminiferous tubule epithelial cell layers and seminiferous tubular diameter an in-vivo rat model.



Caffeinated soft drink drunk experimental rats showed negative effects on the body weight, testicular size and weight, GSI, Tubule epithelial cell layers and diameter seminiferous tubules. The null hypothesis was rejected ( $P < 0.05$ ) and alternative hypothesis was proved and research proves the caffeinated carbonated soft drinks adversely affect the testicular anatomy. Decrease testicular weight and size with impaired spermatogenesis are indicative of lethal effects of caffeinated carbonated soft drinks in the experimental rat's *in-vivo*. The experimental rats showed tendency of obesity induced by soft drinks intake as they increase the appetite and obesity is produced by the sugar content of the drinks. Caffeine may have deleterious effects on the spermatogenesis as proved in the present study. Soft drinks increase the appetite. Obesity and low sperm count may be considered as risk factors for the cardiovascular disease and infertility, yet this is to be proved in the human beings. Experimental rats drinking caffeinated soft drinks showed reduction of testicular weight and size, this proves the caffeinated carbonated soft drinks exerts toxicity on the testicular structures. Decrease in the testicular size was statistically significant ( $p < 0.05$ ) as shown in table 2 and 3. The present study postulates the caffeinated carbonated soft drinks exert toxic effects on the testicular micro anatomy and spermatogenesis. All these findings of present study point towards the toxic effects of caffeinated carbonated soft drinks in *in-vivo* experimental rat model. The findings of present studies are supported by previous studies.<sup>13-17</sup> Previous studies showed toxic effects of caffeinated carbonated soft drinks on the different organs such as the liver,<sup>13</sup> renal tissue<sup>14</sup>, brain tissue<sup>15</sup>, cerebellum<sup>16</sup> and geniculate body.<sup>17</sup> A previous study reported deleterious effects of caffeinated carbonated soft drinks on the kidney. They reported the fructose content of soft drinks induces metabolic syndrome and glomerular hypertension. Aspartame is carcinogenic which might decrease the semen quality of neonates in pregnant women using soft drink.<sup>18</sup> The GSI is reported as an indicator of gonadal maturation,<sup>19</sup> which was decreased in the present study as shown in table 2 ( $p = 0.0001$ ). A previous study<sup>19</sup> proved that the GSI is a biomarker of gonadogenesis and oogenesis in the fish. The findings support the present study. Our findings are also supported by the previous study of Ebbeiling et al.<sup>20</sup> This previous study reported adverse effects of cola soft drinks on the somatic growth and weight in rats. Another previous study<sup>21</sup> proved bad effects of soft drinks on the brain tissue and body. The findings of this previous study are in full agreement with the present study. Purkinje cells of cerebellum were shrunken in rats fed on soft drinks was reported by a previous study.<sup>22</sup> The findings of present study are supported by different previous studies.<sup>23-25</sup> The present study concludes the caffeinated carbonated soft drinks are not

good for health as they predispose to the obesity, metabolic syndrome, coronary artery disease and infertility.

## CONCLUSION

The caffeinated carbonated soft drinks exerts toxic effects on the on the body weight, testicular size, testicular weight, GSI, seminiferous tubule epithelial cell layers and seminiferous tubular diameter an *in-vivo* rat model. Both gross and microscopic anatomy of testes was disturbed in the experimental rats.

**Conflict of Interest:** The study has no conflict of interest to declare by any author.

## REFERENCES

1. Ayuob N, ElBeshbeishy R. Impact of an Energy Drink on the Structure of Stomach and Pancreas of Albino Rat: Can Omega-3 Provide a Protection? PLoS ONE 2016; 11(2): e0149191.
2. Seifert SM, Achache JL, Hershorin ER, Lipshultz SE. Health effects of energy drinks on children, adolescents, and young adults. *Pediatr* 2011; 127(3):511–28.
3. Gupta N, Brown JA. Energy drinks: Health risks and toxicity. *Med J Aust* 2012; 196(1): 46–9.
4. Soliman NBE, Kallen NK, Abd El Samad AA. Effect of omega-3 versus omega-6 fatty acids on induced ulcerative colitis in male albino rat. light and electron microscopic study. *Egypt J Histol* 2010; 33:620–34.
5. Akande IS, Banjoko OA. Assessment of biochemical effect of Power Horse energy drink on hepatic, renal and histological functions in Sprague Dawley rats. *Ann Rev Res Biol* 2011; 1:45–56.
6. Attila S, Cakir B. Energy-drink consumption in college students and associated factors. *Nutr* 2011; 27(3):316–22.
7. Spite M. Deciphering the role of n-3 polyunsaturated fatty acid-derived lipid mediators in health and disease. *Proc Nutr Soc* 2013; 72(4): 441–50.
8. Kangwan N, Park JM, Hahm KB. Development of GI-safe NSAID; progression from the bark of willow tree to modern pharmacology. *Curr Opin in Pharmacol* 2014; 19:17–23.
9. Ebuehi OA, Ajayi OE, Onyeulor AL, Awelimobor D. Effects of oral administration of energy drinks on blood chemistry, tissue histology and brain acetylcholine in rabbits. *Nig Q J Hosp Med* 2011; 21(1):29–34.
10. Sadowska J. Evaluation of the effect of consuming an energy drink on the concentration of glucose and triacyl glycerols and on fatty tissue deposition. A model study. *Acta Sci Pol Technol Aliment* 2012; 11(3): 311–8.

11. Crişan M, Munteanu C, Roşioru C, Lang C. Red bull induces biochemical changes in Wistar rat liver. *Ann RSCB* 2013; 18(2):118-22.
12. Kolnes AJ, Ingvaldsen A, Bolling A, Stuenkel JT, Kreft M, Zorec R, et al. Caffeine and theophylline block insulin-stimulated glucose uptake and PKB phosphorylation in rat skeletal muscles. *Acta Physiol (Oxf)* 2010;200(1):65-74.
13. Rath M. Energy drinks: What is all the hype? The dangers of energy drink consumption. *J Am Acad Nurse Pract* 2012; 24 (2): 70-6.
14. Khayyat L, Sorour J, Al Rawi M, Essawy A. Histological, ultrastructural and physiological studies on the effect of different kinds of energy drinks on the liver of Wistar Albino Rats. *J Am Sci* 2012; 8 (8):688-97.
15. Akande IS, Banjoko OA. Assessments of biochemical effect of Power Horse energy drink on hepatic, Renal and histological functions in Sprague Dawley Rats. *Ann Rev Res Bio* 2011;1 (3): 45-56.
16. Adjene JO, Emojevwe V, Idiapho DE. Effects of long term consumption of energy drinks on the body and brain weights of adult Wistar rats. *J Exp Clin Anat* 2014;13(1):17-20.
17. Eluwa MA, Inyangmme II, Akpantah AO, Ekanem TB, Ekong MB, Asuquo OR, et al. A comparative study of the effect of diet and soda carbonated drinks on the histology of the cerebellum of adult female albino Wistar rats. *Afr Health Sci* 2013;13 (3): 541-5.
18. Adjene JO, Emojevwe V, Igbigbi TS. Morphological effects of long term consumption of energy drinks on the intracranial visual relay centers of adult Wistar Rats. *Ann J Afr* 2014;3(1): 275-85.
19. Adebiyi FA. The Sex Ratio, Gonadosomatic Index, Stages of Gonadal Development and Fecundity of *Sompat Grunt, Pomadasys jubelini* (Cuvier 1830). *Pak J Zool* 2013; 45(1) 41-46.
20. Ebbeling CB, Feldman HA, Chomitz VR, Antonelli TA, Gortmaker SL, Osganian SK, et al. A randomized trial of sugar-sweetened beverages and adolescent body weight. *New Eng J of Med* 2012;367:1407-1416.
21. Adjene JO, Emojevwe V, Idiapho DE. Effects of long term consumption of energy drinks on the body and brain weights of adult Wistar rats. *J Exp Clin Anat* 2014;13(1):17-20.
22. Eluwa MA, Inyangmme II, Akpantah AO, Ekanem TB, Ekong MB, Asuquo OR, et al. A comparative study of the effect of diet and soda carbonated drinks on the histology of the cerebellum of adult female albino Wistar rats. *Afr Health Sci* 2013;13 (3):541-5.
23. De Ruyter JC, Ooshof MK, Seidell JC, Katan MB. A trial of sugar-free or sugar-sweetened beverages and body weight in children. *New Eng J Med* 2012; 367: 1397-1406.
24. Shendiakova A., Rooney K, Boakers RA. Metabolic and behavioral effects of sucrose and fructose/glucose drinks in the rat. *Eur J Nutr* 2012;51: 445-54.
25. Sandner G, Angst MJ, Guibertau T, Guignard B, Nehlig A. Effects of caffeine or RX821002 in rats with a neonatal ventral hippocampal lesion. *Front Behav Neuro Sci* 2014;8(15):1-9.