

Effects of Medroxy Progesterone Acetate (Injectable Contraceptive) on Endometrium (Uterus) of Adult Albino Rats

Soofia Nigar¹, Izhar Fatima² and Aisha Abdul Haq¹

ABSTRACT

Objective: To evaluate the effects of Medroxy Progesterone Acetate (Injectable contraceptive) on endometrium (uterus) of adult female albino rats.

Study Design: Experimental study.

Place and Duration of Study: This study was conducted at animal house of Dow University of Health Sciences (DUHS), The Institute of Basic Medical Sciences (IBMS) and Dow Diagnostic Research and Reference laboratory (DDRRL) from March 2012 to August 2012.

Materials and Methods: Seventy two female albino rats were selected randomly which were later divided into three groups, named Group A, Group B and Group C. These groups were then subdivided into three subgroups depending on the duration of treatment. Treatment was given for one, two and three months. Group A (n=24) animals were served as controls. Group B as treated (n= 24) and were given MPA (3mg/ kg) according to body weight of rat. Group C, treated group (n= 24) was given double dose of MPA (6 mg/ kg.). Injections (MPA) were given only once at the commencement of experiment to both treated groups; B and C. After 1, 2 and 3 months, the female albino rats were dissected and the uterus was removed for observation of morphological and histological changes. Hematoxylin and Eosin were used to stain uterine tissues while collagen fibers were stained with Masson's trichrome. Ocular and stage micrometer were used to notice the histological changes in endometrium. Non-parametric test; Kruskal Wallis and Tukey's were applied for statistical analysis between the group variables.

Results: On comparison of control Group A with the treated group B and C, revealed significant changes. Endometrial thickness was reduced significantly in the treated Group B and Group C (p values <0.005). Histologically significant changes were observed in uterine tissue.

Conclusion: MPA was found out to produce marked fibrotic changes and causes decreased thickness of endometrium. The study was aimed to increase public awareness regarding possible adverse effects of contraceptive injections on women's health; therefore will be valuable for clinical practice

Key Words: Contraception, Medroxy Progesterone Acetate (MPA), Steroid hormone, Endometrium, Fibrosis

Citation of article: Nigar S, Fatima I, Haq AA. Effects of Medroxy Progesterone Acetate (Injectable Contraceptive) on Endometrium (Uterus) of Adult Albino Rats. Med Forum 2017;28(6):140-143.

INTRODUCTION

Prevention of conception by using any contraceptive technique including oral drugs, injections and devices is considered as contraception.¹ Rapid rise in population is a problem faced by several countries and it gives motivation to investigate acceptable and effective methods of birth control that are less expensive, trustworthy and harmless for women. Moreover high maternal mortality rate is an issue in several developing countries which is again because of excessive child birth.

¹. Department of Anatomy / Pathology², Dow University of Health Sciences, Karachi.

Correspondence: Dr. Soofia Nigar, Associate Professor, Department of Anatomy, Dow University of Health Sciences, Karachi.

Contact No: 03332204437

Email: drsoofianigar71@hotmail.com

Received: April 09, 2017;

Accepted: May 12, 2017

In spite of recent advances in contraceptive technology, the ideal contraceptive has not yet been founded.

MPA vial contains 150 mg Medroxy Progesterone Acetate (MPA). It is steroidal compound with biological activity similar to naturally occurring hormone progesterone.³ MPA inhibits the production of gonadotropin hormone which in turn prevents ovulation. It decreases tubal muscular contractility which affects transmission of ovum to the uterus. MPA effects on thickness of endometrium⁴ and acts on hypothalamic-pituitary-ovarian axis throughout menstrual cycle. These injections prevent the ovulation. This act of steroid is vital for the effectiveness of MPA. The frequency of Gonadotropin Releasing Hormone pulses are reduced by the Progesterone. As frequency of Luteinizing Hormone pulses plays major part in ovulation, the effect of progesterone effectively help for contraception purpose. When MPA is injected through intramuscular route, level of serum progesterone seems to increase, suppressing the secretion of anterior pituitary gland to release Follicle Stimulating Hormone and Luteinizing Hormone.⁵

Contraceptive injections (MPA) are available at low cost and can be easily used. Because of this ease, MPA injections are widely used without considering its side effects. This study

Pointed out towards the adverse consequences of drug.⁶ There are studies evaluating the effects of MPA on endometrium. Numerous family planning centers are functioning in Karachi where the drug is readily available without informing any hazards of the injection. It is expected that lack of awareness of side effects will emerge as a major community health burden in coming years.

MATERIALS AND METHODS

Institutional Review Board (IRB) of Dow University of Health Sciences approved all the procedures that were conducted in this study.

Inclusion criteria:

1. Adult female albino rats of Wistar strain were selected for this experimental study.
2. Age range between 90 to 120 days
3. Weight about 190g-220g.

Exclusion criteria: Pregnant Female Rats.

Sample Selection; Animal House of Dow University of Health Sciences (DUHS) provided Seventy two albino rats. Then selected rats were divided into three groups; Group A, Group B and group C. All three groups were further subdivided into three subgroups (each sub –

group comprising 8 animals). Sample size was determined by applying statistical consideration which concluded that each sub- group should comprise at least 8 rats to obtain statistically significant results using statistical test. Control group A had 24 animals. First treated group B having 24 rats, was given MPA (3mg/kg) according to body weight of rats. Group C , second treated group (n= 24) was given double dose of MPA (6 mg/ kg.).

At the commencement of experiment, Injections (MPA) were given only once to both treated groups, B and C. After 1, 2 and 3 months, the female rats were sacrificed under deep Ether anesthesia. A midline abdominal incision was given, uterus was dissected and preserved in 10% formalin for 24-48 hours for fixation and tissues were stained with Hematoxylin and Eosin. Later micrometry was performed to observe morphometric changes in uterus.

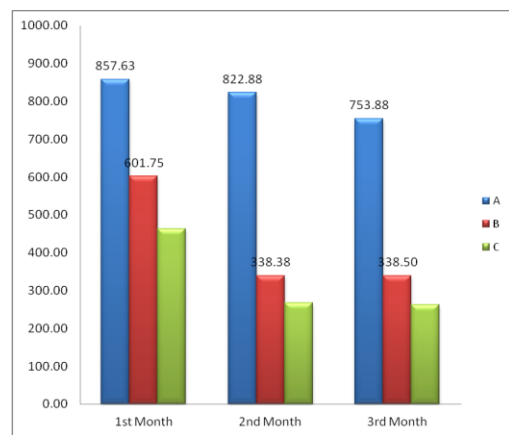
After gross and histological observation, the data was recorded. Kruskal Wallis and Tukey's test from SPSS Version 16 were used to evaluate non-parametric variable between control and treated groups..

RESULTS

The study plan was to observe differences in endometrium of MPA injected groups and control group.

Table No.1: Statistical Analysis and Comparison of Mean thickness of Endometrium of Albino Rats in Control and Treated Group after (1, 2 and 3 Months Treatment)

Group		Thickness of Endometrium(μ m) after 1 st month	Thickness of Endometrium(μ m) after 2 nd month	Thickness of Endometrium(μ m) after 3 rd month
A	Mean \pm SD	857.625a \pm 63.500	753.875a \pm 53.467	564a \pm 34.147
B	Mean \pm SD	601.75b \pm 59.668	338.5b \pm 34.025	415.125b \pm 33.194
C	Mean \pm SD	462.75c \pm 79.260	262.5c \pm 30.076	260.125c \pm 28.732
A V/S B	P value	<0.005	<0.005	<0.005
A V/S C	P value	<0.005	<0.005	<0.005
B V/S C	P value	0.001	0.003	<0.005



Graph 1: Mean Thickness of endometrium (μ m) of Uterus of Female Albino Rats in Different Groups at Variable Time Interval

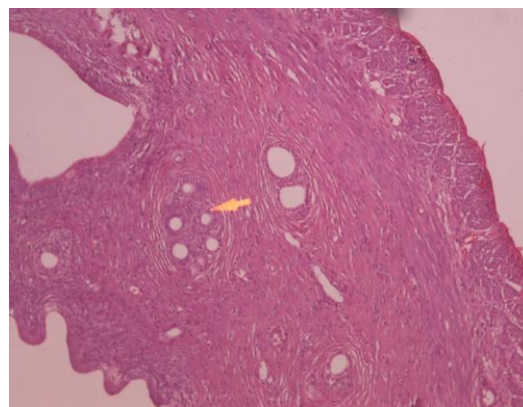


Figure No.1: Hematoxylin and Eosin stained, 5 micrometer thick, transverse section of uterus from control group –A (3-months treated) rat showing (arrow) presence of epithelium, several dilated gland and endometrium and myometrium. Photomicrograph $\times 10$

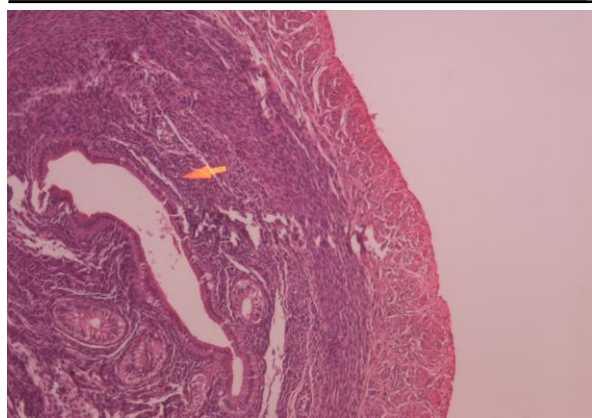


Figure No.2: Hematoxylin and Eosin stained, 5 micrometer thick, transverse section of uterus from group-B (2-months treated) rat indicated reduced height of epithelium (Epi), reduced thickness of endometrium (endo). Photomicrograph x10

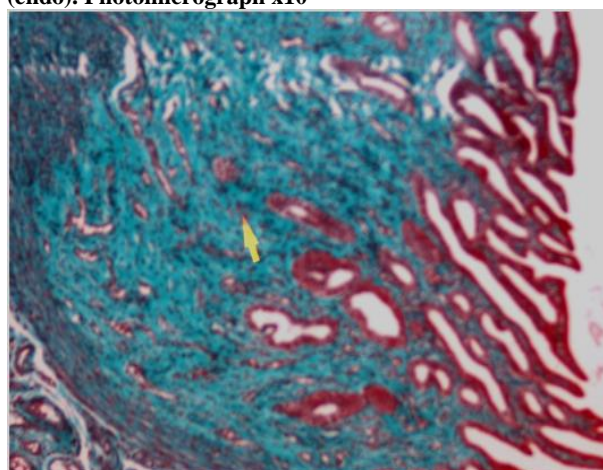


Figure 3: Masson's Trichrome stained 5 micrometer thick section of uterus shows (arrow) marked fibrosis (collagen fiber) in endometrium from group- B (2 months of treatment). Photomicrograph x10

The mean thickness of endometrium was recorded in different groups at different time interval as shown in Table -1 and graph-1. The thickness of endometrium in group B and group C were decreased significantly ($P < 0.005$) as compared to group A. Stained sections of control group by Hematoxylin and Eosin revealed endometrial thickness. However in Group B and C, the thickness was decreased.

DISCUSSION

Globally around 16 million women use injection for contraceptive purpose according to W.H.O research.⁷ Experimental findings of the research provided evidence of progressive reduction (proportional to duration of treatment) in thickness of endometrium after injectable contraceptive.^{8,9} Progesterone decrease proliferation of endometrium through binding to specific hormone binding proteins known as progesterone receptors (PRs). PRs are nuclear proteins

found in epithelial, stromal and smooth muscle cells of the uterus.^{10,11} these receptors have high affinity to progesterone. In agreement to studies previously performed, our study also showed that MPA decreased the endometrial thickness and increased the fibrosis.^{12,13} This was considered to be antiproliferative effect of progesterone on endometrium and chemical ablation of endometrium.^{14,15} Significant increase in elastic, collagen and reticular fibers observed in endometrium are likely to indicate degenerative changes and cell damage. The study provide supporting evidence for the process of fibrosis, previously mentioned by other investigators.^{16,17,18} and similarly reduction in height of epithelium was observed in treated rats. Epithelial discontinuity through either blood or mucus with leukocytes migration in the lamina propria is known as epithelial damage.^{19,20, and 21} Vacuolation and reduce height of epithelium indicate cell damage. Such results may be attributed to suppression of ovarian cycle causing endometrial atrophy.^{22,23} Glands in stroma of endometrium was significantly decreased in injected groups. Results are reinforced by previous researches. Augmented fibrosis and degeneration may have caused the reduction in endometrium.^{24,25}

CONCLUSION

On the basis of present study, it is concluded that MPA produces marked gross and histological changes in uterus. It decreases thickness and fibrosis of endometrium in female albino rats and increased the risk of cervical carcinoma. The study is aimed to increase awareness of possible adverse outcome by these injections and this will ultimately play a vital role in counseling of female patients in clinical practice. Role of media is crucial in this regard.

Acknowledgements: I acknowledge Dr Aisha Abdul Haq for assistance with particular technique, methodology and Dr Izhar Fatima who provided insight and expertise that greatly assisted the research and references writing..

Conflict of Interest: The study has no conflict of interest to declare by any author.

REFERENCES

1. Bakry S, Merhi OZ, Trudy J, Mahmoud SM, Fadiel A, Naftolin F. Depot-medroxy progesterone acetate. Arch Gynecol Obstet 2008; 278:1-12.
2. Kittur N, Secura GM, Peipert JF, Madden T, Finer LB, Allsworth JE. Comparison of contraceptive use between the Contraceptive CHOICE Project and state and national data. Contraception 2011; 83: 479-85.
3. Guyton AC. Female physiology before pregnancy and female hormone. In: Guyton and Hall

- Textbook of Medical Physiology. 12th ed. Saunderson Philadelphia; 2011.p. 981-98.
4. Lortlar N, Kilie S, Peker T, Zulfikaroglu T, Omerogla S, Denix E, et al. The long-term effects of progesterone-only contraceptives on endometrium and ovary in rats. *Arch Gynecol Obstet* 2010; 281:1051-59.
 5. Hardman GJ, Limbard EL, Gilman GA. Estrogen and Progestin. *The Pharmacological Basis of Therapeutics*. 10th ed. McGraw-Hill; 2001.p. 1602-3.
 6. Berenson AB, Odom SD, Radecki BC, Rahman M. Physiologic and psychological symptoms associated with use of injectable contraceptive a 20 microgram oral contraceptive pills. *Am J Obstet Gynecol* 2008; 199: 351-2.
 7. Benagiano G, Diczfalussy E, Goldzieher JW, Gray R. Multinational comparative clinical evaluation of two long-acting injectable contraceptive steroids: Norethisterone oenanthate and medroxy progesterone acetate: *Contraception* 1977;17: 395-407.
 8. Hassan MA, Naim MM, Mahmoud HS, Badr MF. Effect of Monthly Injectable Contraceptive (Mesigyna) on uterus of adult Female Albino Rat: Histological and Immuno histochemical Study. *Egypt J of Hosp Med* 2006; 22: 80-97.
 9. Quanxi U, Athilakshmi K, Francesco J, DeMayo JP, Lydon PS, Cooke HY. The Antiproliferative Action of progesterone in uterine Epithelium is mediated by Hand2. *Science* 2011; 331:912-16.
 10. Gomes JC, Rosa SB, Garcia AC, Japur A, Turatti CS, Vieira K, et al. Effect of levonorgestrel-releasing intrauterine system on cell proliferation, as expression and steroid receptors in endometriosis lesion and normal endometrium. *Oxford J* 2009;24: 2736-45.
 11. Pan H, Deng Y, Pollard JW. Progesterone blocks estrogen-induced DNA synthesis through the inhibition of replication licensing. *Proc Natl Acad Sci* 2006; 103:14021-5.
 12. Myomeshill DG, Moore AB, Kissling GE, Flagler ND, Elizabeth N, Chine JM, et al. Effects of Hormonally Active Agent on Steroid Hormone Receptor Expression and cell proliferation in Myometrium of ovariectomized Macaques. *Hum Reprod J* 2011; 102:112.
 13. Hickey M, Krikum G, Kodaman P, Fredrick S, Carati C, Lockwood CG. Long-term progestin-only contraceptives result in reduced endometrial blood flow and oxidative stress. *J Clin Endocrinol Metab* 2006; 91: 3633-38.
 14. Lizarelli PM, Martins WP, Vieira CS, Soares GM, Franceschini SA, Ferrianni RA et al. Both a combine oral contraceptive and depot medroxyprogesterone acetate impair endothelial function in young women. *Contraception* 2009; 79:35-40.
 15. Pridjian G, Schmit V, Schreiber J. Medroxy progesterone acetate: receptor binding and correlated effects on steroidogenesis in rat granulosa cells. *J Steroid Biochem* 2008; 26:313-9.
 16. Mirsky ML, Lakshmi S, Christopher H, Potter MD, Chapin RE, Cappon GD. Histological and cytologic detection of endocrine and Reproductive Tract. Effects of Exemestane in Female rats treated for up to twenty-eight days. *Toxicol Pathol* 2011; 39:589-605.
 17. Gerez JR, Frei F, Camargo IC. Histological assessment of ovaries and uterus of rats subjected to nandrolone decanoate treatment. *Contraception* 2005; 72: 77-80.
 18. Lee KY. Indian hedgehog is a major mediator of progesterone signaling in the mouse uterus. *Nat Genet* 2006; 38:1204-6.
 19. Kim JJ, Chapman D. Role of progesterone in endometrial cancer. *Semin Reprod Med* 2010; 28:81.
 20. Wonodirekso S, Danayan L, Affandi B, Siregar B, Barasila AC, Rogar WP. Endometrial epithelial integrity and subepithelial reticular fibre expression in progestin contraceptive acceptor. *Human Repro J* 2000; 15: 189-96.
 21. Wild LA, Steinberg WJ, Nel M. Sonar finding of Uterus in patient on medroxy progesterone acetate (Depo Provera)150 mg injection. *SA Fam Pract* 2009; 51: 486-8.
 22. Judge S, Peterman A, Keesbury J. Provider determinants of emergency contraceptive counseling and provision in Kenya and Ethiopia, *Contraception* 2011; 83 :486-90.
 23. Rebecca Say, Diana M. Contraceptive choice for young people. *J Fam Plann Reprod Health Care* 2009; 35: 81-5.
 24. Vanhegan G. Contraception in the under-16s; issues of confidentiality and choice of methods. *Am J Obstet and Gynecol* 2008; 10: 22-26.
 25. Lidgegaard S. Hormonal contraception and risk of venous thromboembolism. National follow up study. *Br Med J* 2009; 339: 2890.